

Aus der Universitäts-Hautklinik Tübingen
Abteilung Dermatologie (Allgemeine Dermatologie mit Poliklinik)
Ärztlicher Direktor: Professor Dr. M. Röcken

**3D-HISTOLOGY AND MALIGNANT SOFT TISSUE
SARCOMAS OF THE SKIN
Local recurrence rate and growth pattern**

INAUGURAL-DISSERTATION
zur Erlangung des Doktorgrades
der Medizin

der Medizinischen Fakultät
der Eberhard Karls Universität
zu Tübingen

vorgelegt von
SIMONE GABRIELE EDER
aus
Böblingen

2007

Dekan: Professor Dr. I. B. Autenrieth

1. Berichterstatter: Professor Dr. H. Breuninger

2. Berichterstatter: Professor Dr. H.-D. Rennekampff

TABLE OF CONTENTS

1	BACKGROUND	1
1.1	INTRODUCTION.....	1
1.2	DERMATOFIBROSARCOMA PROTUBERANS	4
1.3	MALIGNANT FIBROUS HISTIOCYTOMA	9
1.4	MALIGNANT LIPOSARCOMA	14
1.4.1	<i>MYXOID/ ROUND CELL LIPOSARCOMA</i>	15
1.4.2	<i>MIXED-TYPE LIPOSARCOMA/ LIPOSARCOMA NOT OTHERWISE SPECIFIED</i>	17
2	MATERIALS AND METHODS	19
2.1	CLINICAL DATA	19
2.2	SURGERY AND PATHOLOGY.....	19
2.3	DEFINITIONS.....	21
2.4	STATISTICAL ANALYSIS	21
3	RESULTS	22
3.1	PATIENTS AND TUMOUR CHARACTERISTICS.....	22
3.1.1	<i>DIAGNOSIS DFSP</i>	23
3.1.2	<i>DIAGNOSIS MFH</i>	25
3.1.3	<i>GEOMETRICAL GROWTH PATTERN</i>	27
3.2	RECURRENCE	28
3.2.1	<i>DFSP RECURRENCE</i>	29
3.2.2	<i>MFH RECURRENCE</i>	29
3.3	PATIENTS WITH DIAGNOSIS LIPOSARCOMA	31
3.4	PATIENTS WITHDIAGNOSIS LEIOMYO-/ RHABDOMYOSARCOMA	32
4	DISCUSSION	33
5	SUMMARY	39
6	APPENDIX	42
6.1	TABLES.....	42
6.2	FIGURES	47
6.3	QUESTIONNAIRE OF CURRENT MEDICAL STATE.....	51
7	REFERENCES	52

1 BACKGROUND

1.1 INTRODUCTION

Malignant soft tissue sarcomas of the skin are a seldom tumour entity which often are growing slowly over years and tend to local recurrence. Most commonly diagnosed are dermatofibrosarcoma protuberans (DFSP) and malignant fibrous histiocytoma (MFH). The diagnosis of liposarcoma, leiomyo- and rhabdomyosarcoma of the skin is even more rarely. The category of malignant soft tissue tumours of the skin has in addition to the potential for locally destructive growth and recurrence a significant risk of distant metastasis depending on histological type and grade.¹

The role of adjuvant or neoadjuvant radiotherapy is still controversial discussed. In case of questionable clear resection margins it may reduce the probability of local recurrence. Radiotherapy can also be helpful to reduce tumour mass before surgery is carried out.

No effective chemotherapy as a means in treatment has so far been established. However recent molecular findings about oncogenetic pathogenesis of DFSP made it possible to interrupt the tumour growth stimulation through imatinib, a tyrosinkinase inhibitor, and therefore in future may have the potential as a first- line therapy for patients with DFSP that is locally advanced and not amenable to surgery or radiation.² The specific use of imatinib, optimal dosage and duration of therapy is subject of ongoing clinical studies.

Surgery remains the principal therapeutic modality in treatment of soft tissue sarcomas of the skin. Especially negative resection margins are the most important part of surgical therapy since these tumour types have the same asymmetrical growth pattern with subclinical spreads. If these subclinical outgrowths are insufficient detected, soft tissue sarcomas of the skin tend to local recurrence. Limiting factors of surgery are the tumour size and expansion into surrounding anatomical structures.

There are 3 modalities of histological processing the surgical excised material:

1. Conventional histology with following wide excision
2. micrographic guided surgery with cryostatic sections
(Mohs Micrographic Surgery)
3. 3D-histology with paraffin sections induced by Breuninger et al.

Method 1:

The technique of wide excision requires large resection margins of at least 3cm plus the underlying structures to achieve negative margins. Wide local excision uses conventional vertical histological sections which assess < 1% of the total tumour.³ General reported local recurrence rates range with wide excision range from 16.6 to 60%.⁴

Method 2:

Frederic E. Mohs was the first to describe histological examination of serial surgical wound margins in cutaneous tumour surgery accompanied by histological examination of serial horizontal excision margins including the bottom in frozen sections and is called in literature "Mohs Micrographic Surgery (MMS)".⁵ Local recurrence rates seemed to be lower than after wide excision and range from 0 to 6.6%.^{6 7 8}

Method 3:

Breuninger et al. introduced the technique of complete three-dimensional histology of the excision margins including the base with paraffin sections, later called "3D-histology".³ In the treatment of malignant skin tumours this method already achieved local recurrence rates between 0-4%.⁹

The subclinical spreading areas can be detected very sensitively and be localised topographically by the methods 2 and 3. Following surgery can be guided through exact geometrical localisation until tumour-free margins are achieved. In contrast to conventional histology with wide safety margins, 3D-histology guided surgery preserves functionally vital tissue, covers all margins and achieves better esthetical results. Paraffin sectioning provides better slides for microscopy and histological tumour diagnosis can be made more

specifically. Therefore the probability to obtain real RO resection with these methods of surgery for soft tissue sarcomas is very high. However cryostatic sectioning used in Mohs micrographic surgery causes difficulties in handling large excision material fails in detecting questionable tumour spreads and is more time-intensive. Additionally frozen sections create higher costs which is also a remarkable factor for the overall clinical treatment.

Therefore this study was done to review the rate of local recurrence, death of disease and outcomes of long-term follow-up for malignant soft tissue sarcomas treated by surgery guided through 3D-histological margin control in paraffin sections with its high sensitivity. Medical records of patients treated by this method at the department of dermatology at the University of Tübingen since 1982 have been reviewed. The course of disease from patients treated after 1992 was collected prospectively. Clinicopathological characteristics such as localisation, tumour size, safety margin, number of re-excision necessary to achieve tumour-free margins and geometrical growth pattern in relation to the histological diagnosis have been examined in our cohort. Patients with diagnosis of liposarcoma are discussed separately.

1.2 DERMATOFIBROSARCOMA PROTUBERANS

Dermatofibrosarcoma protuberans (DFSP) is a fibroblastic-derived tumour of intermediate malignancy which occurs only in the skin.^{10 11 12} It grows slowly and locally infiltrative, and only rarely metastasises. Normally, the tumour is localised to the trunk and proximal extremities and tends to recur locally.^{10 13} The average age of the patients is 40 years but the tumour can also occur in childhood or even congenitally.^{10 14} In children the disease is referred to as giant cell fibroblastoma.¹⁵ Both sexes are affected equally. It is a rare tumour (< 1: 100 000 per year) with a low mortality rate.¹⁴ Distant metastases is rare (< 5%), and patients with fibrosarcomatous change or with persistent local disease (positive surgical margins or multiple recurrences) are at higher risk.² Fibrosarcomatous change in DFSP is a type of tumour progression and is associated with a significantly more aggressive clinical course.¹⁶ Metastases into the lungs have been reported.¹⁷ There is also a high likelihood of local recurrence, particularly when the initial surgical resection is not complete.¹⁸

MACROSCOPY

The clinical picture shows an uncharacteristic compact, flat or elevated and irregular contoured node which in some cases occurs multinodular. The coloration is often brown-yellow or red-tinged but usually skin-coloured. It is painless and remains sometimes constant for years. The compact consistency of the lesion is the main characteristic but clinical diagnosis can not be made without doubt.¹⁵ Gloster et al. describe the anatomic distribution of DFSP with 50-60% on the trunk, 25% on the limb and 10-15% in the head and neck area.¹⁹

HISTOLOGY

Microscopically a spoke-wheel structure with thickly clustered, atypical spindle-shaped and slightly pleomorphic cells is characteristic. There are many unusual histological variants as shown in **TABLE 1**.¹⁴

TABLE 1: Unusual histological variants of DFSP

- Atrophic DFSP with morphealike plaques
- DFSP with giant cell angiofibroma
- DFSP with granular cells
- Fibrosarcomatous DFSP
- Myxoid DFSP
- Palisaded DFSP
- Pigmented DFSP (Bednar Tumour)
- Sclerosing DFSP

The spread of the tumour usually takes place at the dermal- subcutaneous border. It infiltrates the dermis and depending on the duration also the subcutis and the structures below.²⁰ Immunostaining with CD34, factor XIIIa and S100 can be useful for the differentiation from benign or malignant fibrous histiocytoma, dermatofibroma, neurofibroma, desmoplastic melanoma and others. DFSP usually reacts very strongly with antibodies against CD34 but negatively with antifactor XIIIa, in contrast to dermatomyofibroma.²¹ The diagnosis is established histological after incision or excision biopsy.

MOLECULAR PATHOGENESIS

Genetic research has been able to show chromosomal translocations or ring chromosomes which occur through a fusion of the chromosome regions 17q22 and 22q13.²² These are precisely the gene locations which code the alpha chain of type I collagen (COL1A1) and the beta chain of platelet- derived growth factors (PDGF β). These ring chromosomes express a COL1A1- PDGF β fusion protein which acts as a continuous stimulator for DFSP cells by binding the PDGF receptor.^{23 24 25}

These pathogenetical discoveries make it possible to interrupt the stimulation of DFSP cells via PDGF β receptor by inhibition of the tyrosinkinase. This mechanism was successfully demonstrated with Imatinib/STI-S71 (Glivec) on DFSP cells in vitro and in selected patients.^{26 27 28}

LOCAL RECURRENCE AND METASTASIS

The recurrence rate after DFSP excision varies widely in literature and is also depending on surgical procedure applied.⁷ Histological subtype, high mitotic index, cellularity, size, location on the head and neck, and recurrent lesions are factors reportedly associated with higher recurrence rates.¹⁸ The most important factor for local control is achieving negative margins. Late recurrence beyond the 5-year follow-up may also occur.⁶

A small fraction of DFSP may metastasise, but these may be typical fibrosarcomas rather than DFSP.²⁹ If metastases do occur they are often found in the lungs, however cases of lymph nodes have also been reported.^{17 18}

TREATMENT OPTIONS

1. SURGERY

The therapy of choice is surgery with continuous histology of the marginal sections including the base of excised material. Since the tumour tends to grow asymmetrically with subclinical spreads and may extend for long distances horizontally, excision with 3D-histology (micrographic surgery) would be a logical treatment.³⁰ The sensitivity of frozen sections is too low, even when immunohistochemistry is applied, and therefore the histological processing of the topographically marked material should be carried out with paraffin sections.¹⁴ This way, subclinical extension and small bundles of a few cells extending into the surrounding tissue can be detected.^{3 31} The exact topographic localisation of tumour spread guides corresponding follow-up excisions until the outer surface of the excised material is free of tumour cells.

All procedures which do not check the section margins run the risk of a higher rate of local recurrences because of the infiltrative growth pattern. This is even true when exaggerated safety margins (3 to 5 cm and more) are used.^{32 33}

The high local recurrence rate after surgical treatment with conventional histology implies an initial radical resection with complete margin control.³⁴ Ah-Weng et al. showed that there is no correlation between tumour size and lateral excision margin.³⁰

Surgical excision with wide margins has been considered the standard therapy for DFSP but also recurrence rates of up to 60% have been reported. The technique of Mohs micrographic surgery further increased the local recurrence rates below 10%. Therefore Mohs micrographic surgery could be considered as the treatment of choice for DFSP.^{30 35 36}

2. RADIATION THERAPY

DFSP is considered sensitive to radiation therapy but high recurrence rates have also been reported.^{37 38 39} The indication for radiation therapy may be considered in the following cases:

1. close or questionable tumour free margins, for example in the case of very large tumours, if there is no good potential for adequate observation alone (50- 60 Gy)
2. positive margins if no re-excision is possible (60 Gy)
3. as primary modality with curative intent in selected cases not amenable to surgical treatment (70- 75 Gy)
4. for palliation (individual adapted doses)⁴⁰

Postoperative radiotherapy results in local control rates of $\geq 85\%$ in patients with positive or close surgical margins. However experience with the use of radiotherapy alone to treat macroscopic disease is limited.⁴¹

3. CHEMOTHERAPY

No effective chemotherapy has been established for the therapy of DFSP. In rare cases Ifosfamide and/ or Doxorubicin may be used but no evidence of efficacy of these or other chemotherapeutica exists.²

4. MOLECULAR TARGETED TREATMENT

Recent molecular research has shown that the probable oncogenetic pathogenesis of DFSP. A rearrangement involving chromosomes 17 and 22, in which the collagen I alpha I gene is fused to the gene for platelet-derived growth factor (PDGF) B-chain leads to a deregulated expression of PDGFB with continuous stimulation of the PDGFR receptor β proteintyrosine kinase which is a promoter of DFSP tumour cell growth.⁴² Imatinib is a selective inhibitor of the tyrosine kinase and inhibits cell growth and promotes apoptosis, as has been shown in murine models and selected patients.²⁶ Also the results of preliminary clinical studies indicate that tyrosine kinase inhibition with imatinib is efficacious and well tolerated at dosages of 400- 800 mg/d.⁴² Current studies suggest the indication for therapy with imatinib as a first- line therapy with locally advanced unresectable or metastatic DFSP and as a neoadjuvant agent with surgery to render tumours resectable or to prevent recurrence.⁴² To define the specific use of imatinib in the treatment of DFSP, the optimal dosage and duration of therapy is subject of further clinical studies.

AFTERCARE

No international recommendations exist for follow-up of DFSP. Breuninger et al. suggest carrying out clinical examination every 6 months for the first three years, then every year and in patients with local recurrences a narrow aftercare. In some cases with dedifferentiated fibrosarcomatous tumours a chest X-ray every 6 months is suggested to be made in order to detect early metastases to the lung.¹⁴

1.3 MALIGNANT FIBROUS HISTIOCYTOMA

Malignant fibrous histiocytoma (MFH) occurs usually in the extremities and was considered as the most common soft tissue tumour in older adults. It is a heterogeneous pathological entity with several histological subtypes (**TABLE 2**) and presumably derived from histiocytes that are capable of fibroblastic transformation first described by Stout and associates in the early 1960's.⁴³ However there are controversial opinions about its pathogenesis and the validity as a clinicopathological entity.⁴⁴ Recent clinicopathologic, ultrascructural and immunohistochemical studies have shown that malignant fibrous histiocytomas are not derived from histiocytic “facultative fibroblasts” and many neoplasm so diagnosed actually are pleomorphic subtypes of other sarcomas.⁴³ The actual WHO-Classification uses pleomorphic malignant fibrous histiocytoma and undifferentiated pleomorphic sarcoma NOS (not otherwise specified) synonymously. Also the myxoid variant of MFH is now called myxofibrosarcoma and remains as distinctive and discrete entity.¹

TABLE 2: Subtypes of malignant fibrous histiocytoma

- | |
|---|
| <ul style="list-style-type: none">➤ storiform-pleomorphic➤ giant cell➤ inflammatory |
|---|

Most common subtype of malignant fibrous histiocytomas is cellular neoplasms with a mixture of storiform and pleomorphic areas.

CLINICAL FEATURES

All subtypes present similar clinical features and are therefore being described together. The tumour occurs as a painless, enlarging mass that grows over several months and is most frequently located on the extremities (lower > upper) but also on the retro peritoneum. The majority of cases arise in subfascial soft tissue, while less than 10% are primarily subcutaneous. Around 5% of the patients have metastases at presentation, most often to the lung. It occurs rarely in childhood and the incidence increases with age. Most of the patients are at the age of over 40 with a peak in the 6th and 7th decade. Approximately two thirds are men, and Whites are affected more often than Blacks or Asians.⁴⁵

There is less known about the pathogenesis however a small subset (< 3%) arises at the site of prior radiation therapy and rarely at the site of chronic ulceration. A case of MFH and squamous carcinoma that derived from an old burn scar was reported.⁴⁶

MACROSCOPY

Malignant fibrous histiocytoma appear as a well circumscribed mass which can vary in size depending on the location but in most of cases measure between 5 and 15 cm maximum diameter. The cut surface is variable and may include fleshy areas, admixed with zones of necrosis, cystic, haemorrhage or myxoid change. There are no distinctive macroscopic features which correlate reliably with line of differentiation.¹

HISTOLOGY

The appearance and cellularity of tumours in the general category of high grade pleomorphic (MFH-like) sarcomas is very heterogeneous, since some cases have an extensive fibrous stroma. They all have in common a nuclear pleomorphism, often with giant, spindle and rounded histiocyte-like cells in variant distributions. The storiform growth pattern is typically.¹

IMMUNOHISTOCHEMISTRY

Immunohistochemistry is playing an ancillary role in the diagnosis of MFH and primarily is serving as means to exclude other pleomorphic tumours such as anaplastic carcinoma. Controversy exists as to the extent of immunopositivity required for a given antigen to define a specific line of differentiation. The presence of just rare cells showing positivity for epithelial or myogenic antigens most often has little significance and does not exclude the diagnosis. Histiocytic antigens such as alpha-1-antitrypsin, alpha-1-antichymotrypsin, lysozyme and CD68 play no useful role in the diagnosis because they are present inconsistently and in sarcomas of diverse types. Fibrosarcomas are positive for Vimentin, CD34 and very focally for smooth muscle actin.⁴⁵

MOLECULAR PATHOGENESIS

The molecular pathogenesis of this tumour entity is still poorly understood. Cytogenetic aberrations have been detected in more than 50 cases published as storiform or pleomorphic MFH and MFH NOS. In general the karyotypes tend to be highly complex with intratumoral heterogeneity. The chromosome numbers range in the majority of cases in the triploid or tetraploid range. Telomeric associations, ring chromosomes and/or dicentric chromosomes are frequent. Several proto-oncogenes (SAS, MDM2, CDK4, DDIT3, HMGIC) mapping to chromosome region 12q13-15 appear to participate in the development however no clear relationship with clinical outcome has been found yet.⁴⁵

The occurrence of large chromosome markers in MFH have been demonstrated and are suggested to play a role in tumourgenesis.⁴⁷ Also common gen alterations support the suggest of an overlap in genetic aetiologies between myxoid MFH and pleomorphic liposarcoma.⁴⁸

LOCAL RECURRENCE AND METASTASIS

High grade pleomorphic sarcomas are aggressive and tend to local recurrence and distant metastasis although the recent studies show decreasing rates, probably cause of more immediately efficacious therapy.¹

Complete surgical resection with negative margins at the time of primary tumour presentation is likely to decrease the incidence of local recurrence.⁴⁹ However local recurrence rates and metastatic disease of > 22% after surgical treatment have been reported.⁵⁰

Le Doussal et al. (1996) showed with a multicenter study of 216 patients that besides resection of all macroscopic disease, also adjuvant radiotherapy and histopathological grade are important prognostic factors for disease, metastatic and recurrence free survival.⁵¹ Tumour size (> or = 5 cm), deep depth and high grade are associated with unfavourable prognosis.⁵²

DIAGNOSIS

Diagnosis is primarily made by histology and the immunohistochemical exclusion of other pleomorphic tumours.

CT or MRI can be useful in demonstrating the origin and involvement of surrounding structures however specific diagnosis cannot be made.⁴⁵

TREATMENT OPTIONS

1. SURGERY

The aggressive growth of this malignant tumour indicates radical surgery with histological margin control as the treatment of choice. Comparable to the surgical procedures for DFSP, the most important factor in treatment and prognosis of MFH is to achieve clear tumour-free margins.

Previous reports have confirmed good results of Mohs micrographic surgery for the treatment of DFSP, but there are only few data available in international literature on the potential as a means in treatment of MFH. Mohs micrographic surgery is proving so far to be very useful in treating MFH. It has shown effectiveness on local control and metastasis; however recurrence rates of up to 43% have also been reported.^{53 54}

2. CHEMOTHERAPY

Chemotherapy plays a role as an adjuvant or palliative means in treatment of MFH. However also a reduced ifosamid chemosensitivity, compared to other sarcoma entities, has been detected in MFH lesions.⁵⁵

ILEX Oncology is developing the dihydrofolate reductase inhibitor, piritrexim for the potential treatment of cancer. It is also in phase II clinical trials for MFH.⁵⁶

Another chemotherapeutic agent is ST1571, a tyrosine kinase inhibitor, which significantly inhibited proliferation of MFH cell lines and might be a potent agent for human MFHs.⁵⁷

The efficacy of chemotherapy varies according to the histological type of sarcoma and is even statistically not demonstrated in round cell sarcomas like MFH however the prognosis can be improved when chemotherapy is used as an adjuvant therapy.⁵⁸

3. RADIOTHERAPY

Radiotherapy is a useful adjuvant means in treatment of MFH, however surgery with histological margin control remains the principal therapeutic modality. Multimodality therapy with both surgery and radiotherapy improves local control, particularly in patients with close or positive surgical margins.⁵⁹

A higher local control can be achieved with preoperative radiotherapy in patients presenting primarily with gross total disease and postoperative radiotherapy in patients presenting primarily following gross total excision.⁶⁰

Also the interval between surgery and radiotherapy does not significantly impact the 10-year local control rate.⁶¹

In summary, adjuvant radiotherapy is indicated after minimal excision and for residual tumour (= R1), but the role after complete tumour excision (= R0) is still questionable and be subject of further trials.

1.4 MALIGNANT LIPOSARCOMA

Liposarcomas represent the single most common type of soft tissue sarcoma. Its principal subtypes are separate diseases with different genetics and morphology.¹ The latest WHO classification of malignant adipocytic tumours is shown in **TABLE 3**.

TABLE 3: Histological variants of malignant liposarcoma

- | |
|---|
| <ul style="list-style-type: none">➤ Dedifferentiated liposarcoma➤ Myxoid liposarcoma➤ Round cell liposarcoma➤ Pleomorphic liposarcoma➤ Mixed-type liposarcoma➤ Liposarcoma not otherwise specified |
|---|

Dedifferentiated liposarcomas occur in up to 10% of well differentiated liposarcomas but more probably time-dependent. The most common location is the retroperitoneum and rarely the soft tissue of the extremities, head, neck and trunk. Extremely rare is the occurrence in the subcutaneous tissue.

Pleomorphic liposarcomas are the rarest subtype (< 5%) of liposarcomas and tend to occur in deep soft tissue of the limbs more frequently than retroperitoneal. Only few cases of occurrence in the subcutis have been reported.¹

Well differentiated liposarcoma is the largest subtype (40-45%) of aggressive adipocytic neoplasm. It is a tumour of intermediate malignancy (locally aggressive) that occurs in deep soft tissue of the limbs and retroperitoneum but may also arise in subcutaneous tissue but very rarely in the skin.

Myxoid liposarcoma (MLS) is the second most common subtype (> 30%) of all liposarcomas with predilection for location in the deep soft tissue of the extremities and proximal musculature of the lower extremity.¹

According to their occurrence in soft tissue of the skin and extremities MLS and mixed-type liposarcomas are described more detailed as follows.

1.4.1 MYXOID/ ROUND CELL LIPOSARCOMA

CLINICAL FEATURES

MLS occurs as a painless large tumour mass within the deep soft tissues of the lower extremities, particularly the limb and popliteal region. Some patients also present with a multifocal tumour growth. The incidence is compared to the other subtypes in a younger age group with a peak in the 4th and 5th decade. Both sexes are affected equally.¹

MACROSCOPY

MLS occurs as a well-circumscribed intramuscular tumour mass which is often multinodular. The cut surface is yellow-white and gelatinous in contrast to areas with round cells, which have a white fleshy surface.¹

HISTOLOGY

There is a mixture of uniform round to oval shaped non-lipogenic mesenchymal cells and small signet-ring lipoblasts in a prominent myxoid stroma. One characteristic is the delicate arborisation of the capillary vasculature. Typically no significant mitotic activity, nuclear polymorphism or giant tumour cells can be found. A subset of MLS shows progression to hypercellularity or round cells and is related to a poorer prognosis. The histological presence of gradual transition from myxoid to hypercellular or round cell areas occurs commonly in MLS. Therefore the continual development from myxoid to round cell liposarcoma is being close.

The differential diagnosis of MLS includes a wide range of lesions but is most commonly confused with myxoid malignant fibrous histiocytoma, myxoid chondrosarcoma or myxoid forms of dermatofibrosarcoma protuberans.⁶²

IMMUNOHISTOCHEMISTRY

Immunohistochemistry is for most of the cases not necessary to make the correct diagnosis of MLS. However in some cases, especially with predominant round cell histology, can be useful. The immunohistological reaction is positive with S100 protein.⁶²

Immunostaining using antibodies for topoisomerase-II alpha seems to be useful in recognizing lipoblasts that have been overlooked in hematoxylin-eosin-stained sections, and is a useful marker for diagnosing liposarcoma.⁶³

MOLECULAR PATHOGENESIS

The karyotype of myxoid and round cell liposarcoma shows a typically (> 90% of the cases) translocation of t(12;16)(q13;p11) which leads to the fusion of the *DDIT3* and *FUS* genes and the generation of *FUS/DDIT3* hybrid protein. In rare cases of MLS a translocation of t(12;22)(q13;q12) with following fusion of *EWS/DDIT3* genes has been described. The presence of the *FUS/DDIT3* fusion is highly sensitive and specific for the MLS entity and is absent in other morphological similar tumours.⁶²

LOCAL RECURRENCE AND METASTASIS

Significant prognostic factors for disease-specific survival are for example tumour depth, size, grade, microscopic margin status and certain subtypes.⁶⁴

It is suggested to divide this subgroup into three grades depending on the relative amount of round cell differentiation (grade 1: < 10%, grade 2: 10-20%, grade 3: > 25%) because it showed a correlation with metastasis and survival.⁶⁵

One study showed that 35% of patients with these lesions developed metastases and 31% died of the disease.⁶⁶ The percent of round cell differentiation and spontaneous necrosis were significantly associated with a poorer course of disease and prognosis.

MLS metastasises to the lung and bone but also shows the unusual clinical phenomenon of metastasising to other soft tissue areas such as retroperitoneum or opposite extremity, even before spreading into the lungs. Although brain metastases are rare (< 1%), vigilance is warranted.⁶⁷

1.4.2 MIXED-TYPE LIPOSARCOMA/ LIPOSARCOMA NOT OTHERWISE SPECIFIED

CLINICAL FEATURES

True mixed-type liposarcoma is extremely rare. The large painless tumour mass arises retroperitoneal or intraabdominal and rarely in deep soft tissue of the extremities. Elderly patients are predominantly affected.¹

MACROSCOPY

In most of the cases the tumour mass is large and multinodular with cystic and solid areas. The cut-surface is grey-yellow.¹

HISTOLOGY

Myxoid areas in well differentiated and dedifferentiated liposarcoma occurs frequently and especially in retroperitoneal and intraabdominal location. It is however often a myxoid degeneration or dedifferentiation with myxofibrosarcoma-like features in well differentiated liposarcomas.

The actual mixed-type liposarcoma presents as a morphological mixture of characteristics of myxoid/round cell, pleomorphic and well differentiated liposarcomas:

- small undifferentiated mesenchymal cells, univacuolated lipoblasts, round cells embedded in a myxoid stroma, arborizing vasculature
- variable number of pleomorphic lipoblasts
- adipocytes with variable size, shape and nuclear atypia.¹

MOLECULAR PATHOGENESIS

No specific karyotype abnormality has been found yet for this tumour entity. However in three karyotyped cases the presence of ring or giant marker chromosomes was observed.¹

TREATMENT OPTIONS

1. SURGERY

Surgery still plays the dominant role in treatment of malignant liposarcomas. Particularly the quality of initial local treatment is the most important factor for the tumour progression due to the invasive and metastatic potential. To our knowledge, there are only few articles published in literature about long-term follow-up in treatment with histological margin controlled surgery for malignant liposarcomas of the skin. Results with wide excision in the treatment of liposarcomas of the extremities showed a 5-year survival rate of 79%, however the median follow-up was 36 months.⁶⁸

2. CHEMOTHERAPY

The role of high dose chemotherapy with autologous peripheral blood stem cell transplantation in the treatment of soft tissue tumours is not established however a subgroup could benefit from this therapy.⁶⁹

For metastatic liposarcomas an anthracycline-based regimen with or without ifosamide as front-line therapy is suggested. The role of newer agents (e.g. epothilones, brostallicin) is not yet defined and neither targeted therapy inhibiting vascular endothelial growth factor receptor, RAF kinase, c-Kit or platelet-derived growth factor receptors, which are subjects of ongoing clinical studies.⁷⁰

3. RADIATION THERAPY

When a conservative treatment is feasible, it should combine surgical resection and radiotherapy, brachytherapy being the best suited in previously irradiated patients.⁷¹

Myxoid Liposarcomas showed a statistically significant reduction in size when treated with radiotherapy and this response is greater than that of MFH tumours given the same radiotherapy. Therefore radiotherapy is suggested in combination with surgery in difficult anatomic situations when no adequate surgical excision is feasible.⁷² Small volume treated to $< \text{ or } = 40 \text{ Gy}$ is required to maintain good outcome. The most important parameter appears to be the volume treated to $> \text{ or } = 55 \text{ Gy}$.⁷³

2 MATERIALS AND METHODS

2.1 CLINICAL DATA

The medical records of patients with a malignant soft tissue tumour of the skin who were treated at the department of dermatology at the University of Tübingen from 1982-2005 were reviewed and have been included (n= 131). Data were collected from medical records at our Institution and the Cancer Comprehensive Centre and then be deidentified. Patients with records that contained not enough information about the medical history or records that could not be found were excluded (n= 8). A questionnaire to the current medical state of recurrence and aftercare was primarily mailed and in case of non response within four weeks patients were questioned by phone (**Appendix**, questionnaire). This information provided the basis for the Kaplan-Meier method we used to evaluate the follow-up and recurrence rate (n= 101). Therefore patients with no information about the present medical condition (last medical information corresponds the operation date) were excluded for the Kaplan-Meier survival fit (n= 24). Patients with the diagnosis of liposarcoma (n= 4) and leiomyosarcoma (n= 2) were discussed individually. Data from patients which underwent micrographic surgery with following 3D-histology since 1992 were collected prospectively and used for the evaluation of clinicopathological values such as tumour size, safety distance and geometrical information (n= 84).

2.2 SURGERY AND PATHOLOGY

The diagnosis of malignant soft tissue tumour was made microscopically after incision or excision biopsy at our department or extern. Biopsies not taken at our department were evaluated again from our pathologist to confirm the diagnosis. All patients were surgically treated with following 3D-histology described as follows. The lesion/scar site was outlined. Local anaesthesia was obtained using subcutaneous infusion anaesthesia with diluted mixtures of prilocain/lidocain and ropvacain so called automatic tumescence local anaesthesia (Auto-TLA).⁷⁴ All macroscopic tumour was excised in patients with

remaining clinical lesions. Excision with 5-10mm margins was made around the debulking defect. If only a biopsy scar with no clinical lesion was present, the scar was excised with 5-10mm margins peripheral and deep to the initial biopsy scar. Tissue was divided into multiple specimens including the vertical excision margins and the base (adipose, fascia) of the excised material and sent to the pathologist for rush fixation. All specimens were embedded in paraffin and sectioned in the routine procedure (**FIGURE 1**).^{14 75} Slides were HE stained and interpreted by the surgeon or a pathologist with experience in histopathological interpretation of malignant soft tissue tumours. Immunohistochemistry was not used routinely. If any slide revealed positive margins, the patient then returned to the operative suite and underwent further excision of precise positive area(s) with additional 5-10mm excision margins. The process continued until tumour-free margins were obtained. If the tumour extended deeply into muscle or further, then the procedure was terminated and the patient was referred for wide excision under general anaesthesia and if necessary with interdisciplinary treatment. After the complete excision of the tumour we approached a primary wound closure. Depending on tumour extend flap or graft was performed. In cases where no clear tumour-free margins could be obtained following radiation therapy was applied.

The treatment procedure of surgery with 3D-histology carried out at our department is shown in **FIGURE 2-7**.

There exist no special guidelines for follow-up, however we recommended our patients to carry out clinical examinations along with self-examinations every 6 months for the first three years after the primary excision or first recurrence and thereafter every year. In case of dedifferentiated fibrosarcomatous tumours or MFH additionally chest X-ray, ultrasound of the skin and regional lymph nodes were carried out every six months.

2.3 DEFINITIONS

All patients who presented to our department for definitive therapy (after biopsy, incision or inadequate excision biopsy) were defined as having primary lesions. Local recurrence was defined as a diagnosis of tumour within or contiguous with the previously excised field >3 month after primary therapy.¹⁸ Absence of macroscopically and microscopically tumour parts was defined as R0 (complete resection). R1 was defined as microscopic positive marginal spreads. Tumour cells within loco-regional lymph nodes were defined as lymph node metastases. Tumour deposits in distant organs or non- continuous structures were defined as distant metastases. Event free survival time was calculated from the date of surgery at the department of dermatology UKT to the time of diagnosis of local recurrence, distant metastasis or death of disease.

2.4 STATISTICAL ANALYSIS

The study population (n= 131) was divided into two major groups according to their microanatomy:

1. Patients with diagnosis DFSP (n= 91) and
2. Patients with diagnosis MFH (n= 34).

The minor group contains data of patients with Liposarcoma (n= 4) and Leiomyosarcoma (n= 2) is being discussed separately.

The time to recurrence was modelled by using the method of Kaplan and Meier.⁷⁶ Events were defined as the diagnosis of local recurrence, metastasis or death due to tumour. Local recurrence free survival was the primary endpoint.

The prospectively collected data from patients (DFSP n= 66, MFH n= 18) treated after 1992 at our department were analysed to clinicopathological variables such as tumour size, extension into depth, security margin, excision frequency and aftercare. To determine relationships between these variables the Fisher's exact and chi square test were performed when appropriate.

A p-value < 0.05 was considered as statistically significant. All analyses were performed with JMP® software version 5.1 and in collaboration with the department for medical information processing at the University of Tübingen.

3 RESULTS

3.1 PATIENTS AND TUMOUR CHARACTERISTICS

131 patients with diagnosis of malignant soft tissue tumours of the skin underwent treatment by micrographic surgery with following 3D-histology at the department of dermatology, University of Tübingen between 1982 and 2005 and have been included. In our study population the diagnosis of DFSP (n= 91), MFH (n= 34) and Liposarcoma (n= 4) and Leio-/ Rhabdomyosarcoma (n= 2).

The gender, age and location were a statistically significant risk factor for diagnosis in our study population. DFSP occurred in female and male patients equally; however 68% with diagnosis MFH were males and 32% females (p= 0.018). 62% of the DFSP patients were at the age of 20-50 years, 67% of the MFH patients were older than 50 years at the time of treatment (p= 0.002). The location of DFSP lesions was for 48% the trunk and 30% the upper extremity, and for MFH lesions for 44% the head/neck and 23% the lower extremity (p= 0.001) (**TABLE 4**).

According to the location, there was a significant factor for surgery into depth (p= 0.001) (**TABLE 5**). Surgery extended in case of MFH lesions for 28% into the subcutis and for 72% deeper, DFSP lesions for 57% into subcutis and for 43% deeper.

3.1.1 DIAGNOSIS DFSP

There were 51 females and 40 males with the mean age of 40 years (range, 7-89 years). The anatomic distribution was the trunk (44 patients; 48%), upper extremities (27 patients; 30%), lower extremities (12 patients; 13%) and the head/neck (8 patients; 9%) (**TABLE 4**).

We collected prospectively medical data from 66 patients with DFSP treated after 1992 at our department (**TABLE 5**). Fifty-four patients (64%) with primary and twelve patients (14%) with local recurrent lesions were presented to our department. The first diagnosis was made in 4 cases (6%) at our institution, and 62 cases (94%) at a dermatologist practice. In 7 cases (11%) there was no agreement from our pathologist with the first diagnosis made from the extern dermatologist (fibrous histiocytoma, leiomyoma and lipoma). The mean size of the primary clinical lesion was 48mm (\pm 37mm), with a mean postoperative histological tumour size of 67mm (\pm 40mm). A mean safety margin of 19mm (\pm 12mm) was performed to achieve negative margins. The depth required for tumour clearance was the subcutis (37 patients; 57%), fascia (15 patients; 22%), muscle (11 patients; 18%) and periost/ cartilage (3 patients; 3%). For 2 patients an interdisciplinary treatment was necessary. A 16 years old male with tumour extension centrally into the musculus pectoralis underwent surgery in collaboration with a general surgeon in total anaesthesia to achieve clear tumour margins. For another 54 years old patient surgery was carried out in collaboration with an ophthalmologist due to the tumour location. In 33 cases (50%) tumour-free margins were obtained after the first surgery, in 24 cases (36%) after the first re- excision, for 9 cases (14%) a maximum of three re-excisions was necessary for histological tumour freedom. All patients had a postoperative status of macro- and microscopically tumour absence (= R0). In one patient local recurrence was diagnosed 62 months after treatment at our department. No patient showed distant or lymph node metastases within the follow-up period. Three patients died within the follow-up period, one 65 years old male patient cause of Morbus Hodgkin disease and two female patients (age 52 and 75 years) cause of unknown other causes.

Data from 61 patients were available to analyse the aftercare characteristics. For 32 patients (52%) the aftercare was lead through our department, 29 patients (48%) presented to a dermatologist practice. The aftercare frequency was 12% quarterly (7 patients), 34% (21 patients) half-yearly, 30% (18 patients) yearly and 13% (8 patients) checked irregular the postoperative status or 11% (7 patients) even did not carry out professional aftercare. The means for examination were for 95% (58 patients) palpation, 50% (30 patients) ultrasound of the skin and lymph nodes, 13% (8 patients) blood analysis and chest X-ray, and 5% (3 patients) a computer tomography.

3.1.2 DIAGNOSIS MFH

There were 11 females and 23 males with the average age of 69 years (range, 19- 89 years). The anatomic distribution was the trunk (6 patients; 18%), upper extremities (5 patients; 15%), lower extremities (8 patients; 23%) and the head/neck (15 patients; 44%) (**TABLE 4**).

We collected prospectively medical data from 18 patients with MFH treated after 1992 at our department (**TABLE 5**). Fourteen patients (74%) with primary and four patients (26%) with local recurrent lesions were presented to our department. The first diagnosis was made in 4 cases (21%) at our institution, and 15 cases (79%) at a dermatologist practice. In 1 case (5%) there was no agreement with the diagnosis made from the extern dermatologist (DFSP). The mean size of the primary clinical lesion was 37mm (\pm 32mm), with a mean postoperative histological tumour size of 56mm (\pm 43mm). A mean safety margin of 17mm (\pm 16mm) was performed to achieve negative margins. The depth required for tumour clearance was the subcutis (5 patients; 28%), fascia (1 patients; 5%), muscle (5 patients; 28%) and periost/cartilage (7 patients; 39%). Two patients had synchronous lesions. For 6 patients an interdisciplinary treatment was necessary: ulna amputation (1 patient), leg amputation (1 patient), radiation therapy (3 patients) and patient transfer to ENT clinic due to delicate location retro auricular (1 patient). In 8 cases (44%) tumour-free margins were obtained after the first surgery, in 6 cases (33%) after the first re-excision, for 3 cases (17%) two re-excisions and in one case even 5 re-excisions were necessary for histological tumour freedom. For three patients no clear microscopically tumour-free margins could be achieved.

In eight patients local recurrence was diagnosed after surgery at our department within the follow-up period (six patients with one recurrence (22%), two patients with two recurrences (7%). The mean time to first recurrence was 20 months, the earliest occurrence 5 month, the latest 65 month after treatment. The second recurrence was diagnosed in one patient after 27 months and in the other 53 month after the first treatment at our department. Four patients showed metastases, 1 patient within the lungs, 2 patients within lymph nodes and 1

patient developed both lung and lymph node metastases. Ten patients died within the follow-up period (three cause of the tumour disease, four cause of other diseases and further four due to unknown causes).

Data from 24 patients were available to analyse the aftercare characteristics. For 8 patients (33%) the aftercare was lead through our department, 16 patients (67%) presented to a dermatologist practice. The aftercare frequency was 21% quarterly (5 patients), 24% (6 patients) half-yearly, 21% (5 patients) yearly and 17% (4 patients) the postoperative status was checked irregular or 17% (4 patients) even carried out no professional aftercare. The means for examination were for 95% (22 patients) palpation, 63% (8 patients) ultrasound of the skin and lymph nodes, 48% (11 patients) blood analysis, 35% (8 patients) chest X-ray, and in 26% (6 patients) a computer tomography was performed.

3.1.3 GEOMETRICAL GROWTH PATTERN

We analysed the tumour growth pattern of DFSP (n= 34) and MFH (n= 11) by means of histological reports, where the exact geometrical tumour extends were described clockwise. Tumour spreads could be detected at 1 time (= cord-like), at more than 2 connected times (= sector-like) and at different times (= multiple). According to the processing of the excision material for 3D-histology, the vertical and horizontal growth of three dimensions could be analysed: vertical superficial layer (dermis), vertical subcutaneous layer (depth) and horizontal base.

Our specimen showed the following microscopically features (**TABLE 6**):

There was a statistically significant risk factor for the vertical growth in the depth (subcutaneous layer) ($p= 0.019$).

The DFSP tumours extended subclinical to equal parts vertically into the superficial layer (26% sector-like, 24% multiple, 6% cord-like) and the subcutaneous layer (29% sector-like, 21% multiple, 6% cord-like).

All MFH tumours (100%) showed subclinical vertical tumour extension. The growth was more often vertically in the subcutaneous layer (91%), and there to equal parts cord-like (36%) and multiple (36%), sector-like (19%). If growing vertically superficial (36%), the growth pattern was multiple (27%) and sector-like (9%), however 64% didn't grow in the superficial layer.

Both tumour types grew vertically in both layers (dermis and subcutaneous) in about one third of the cases (DFSP 29%, MFH 27%).

Both tumour types showed in a bit more of half of the cases no growth at the horizontal base (DFSP 59%, MFH 55%). The other half grew at the horizontal base (DFSP 41%, MFH 45%).

Vertical and horizontal growth could be detected in 24% of DFSP tumours, in contrast to MFH tumours, which showed growth in 45% of the cases.

3.2 RECURRENCE

Follow-up data was available for 101 patients (DFSP n= 70, MFH n= 31) who were treated at our department between 1982 and 2005. Twenty four patients (DFSP n= 21/ 23%, MFH n= 3/ 8%) were lost to follow-up because the date of last information about disease was equal to the date of surgery. The follow-up was for 35 patients (35%) over 5 years, for sixty six patients (65%) within 5 years (**TABLE 7**).

Diagnosis was a statistically significant variable for local recurrence ($p= 0.004$), distant metastasis ($p= 0.002$) and death ($p= 0.001$). 27% of MFH lesions and 1% of DFSP lesions developed local recurrence. No metastasis were detected in patients with DFSP, however four patients (13%) with MFH lesions showed distant metastasis. No death of disease occurred in DFSP patients, while ten patients (32%) with MFH died, three (30%) due to disease and seven (70%) cause of other causes (**TABLE 7**).

Non-significant variables for local recurrence were presentation form (primary/ recurrent lesion), localisation, tumour size, number of re-excisions and safety margin.

3.2.1 DFSP RECURRENCE

Mean follow-up was 58 months. The 5-year recurrence free survival 100% and 10-year recurrence free survival 96% (**FIGURE 8**). The local recurrence rate was 2%. One patient had a local recurrence after 62 months. It was not extended and could be treated with the same method again.

Fifteen patients already had a local recurrence diagnosed and treated outside our clinic before treatment at our department (**TABLE 7**). No death or metastases were attributed to DFSP tumour in our study population within the follow-up period (**FIGURE 9**).

3.2.2 MFH RECURRENCE

Mean follow-up was 64 months and mean recurrence free survival 55 months. The 5-year recurrence free survival 71% and 10-year recurrence free survival 65% (**FIGURE 8**). The local recurrence rate was 29%, eight patients had the first local recurrence after a median time of 20 months (between 6 and 65), and two of them developed a second recurrence after the first surgery at our department. One of the patients showed metastasis between first and second recurrence (23 and 27 months after treatment) and died due to the tumour disease 19 months afterwards. The other patient developed a second local recurrence with extension into the corticalis of the local bone structure but no distant metastasis. Interdisciplinary treatment was required.

Five patients already had a local recurrence diagnosed and treated outside our clinic before treatment at our department (**TABLE 7**).

Three male patients died of MFH disease within the follow-up period (10, 24 and 46 months after treatment at our department). All of them had local recurrence, distant metastases and a postoperative status of R1. The age at first surgery at our department was 66, 69 and 70 years, location on head/neck, trunk and lower extremities, and a clinical tumour size of > 40mm. In one case 5 re-excisions were performed with a total safety margin of 60 mm.

The 5-year death free survival was 89% (**FIGURE 9**).

PATIENT 1

A 70 years old male patient was referred to our department for further treatment of a recurrent MFH lesion located on the upper back. The first false diagnosis of DFSP was made outside our department 6 years before presentation to our clinic. Within this period three local recurrences were diagnosed and treated by wide excision. The patient then presented to our department with a 30 mm scar for further treatment. After three re-excisions at our department with surgery into deep musculature, total safety margin of 30mm and 3D-histology no microscopically clear tumour-free margins (= R1) could be achieved. Microscopic examination showed multiple tumour spreads in all directions. The health condition was in progression within the following year, multiple metastases of lungs and loco regional lymph nodes were detected and the patient died due to complications of metastases.

PATIENT 2

A 74 years old female patient presented to our department for surgery with following 3D-histology of a 15mm MFH lesion located on the right forearm. The diagnosis was made by incision biopsy from an extern dermatologist and patient was immediately referred to our department. After the first excision with a safety margin of 20mm and following 3D-histology no microscopically tumour spreads (= R0) could be detected. The patient underwent regular aftercare at our department however developed four years later a local recurrence with involvement of ulna corticalis. An interdisciplinary treatment with en bloc-resection of the proximal ulna, arthroplasty and following radiation therapy was carried out and tumour-free resection margins could be achieved. Aftercare is carried out every six months with chest X-ray and MR- tomography. The patient showed no recurrence or metastases within the period of last follow-up and four years after the ulna amputation.

3.3 PATIENTS WITH DIAGNOSIS LIPOSARCOMA

Four patients with histological diagnosis of liposarcoma (= 3% of total) were in our cohort. All have the gender male and a median age of 54 years (range 38 to 61 years). The localisation is the lower extremity (n= 2), upper extremity (n= 1) and head/neck (n= 1). During the mean follow-up time of 28 months three patients had no local recurrence and in one patient 76 months after treatment at our department local recurrence developed. Two patients died one cause of a glioblastom and one of disease (liposarcoma).

PATIENT 1

A male patient age 54 years presented to UKT with a slowly enlarging growth of a 35mm lesion on the lower extremity. After incision biopsy the histological diagnosis of liposarcoma was made and the patient underwent micrographic surgery with 3D-histology. No tumour spreads could be detected microscopically after last surgery (= R0). After 76 months the patient showed local recurrence and lymph node metastases. Interdisciplinary treatment with radiation therapy was applied, however the patient died of disease 41 months afterwards.

PATIENT 2

A male patient age 61 years presented to UKT with a painless lesion of 45mm on the upper extremity. The first false diagnosis of Lipoma was made by excision biopsy at a dermatologist practice 11 years before presenting to our department. Three excision biopsies were performed until presentation to our department for further treatment was suggested. Our pathologist diagnosed liposarcoma and the patient therefore underwent surgery with 3D-histology at our department. The tumour growth was sector-like in the subcutaneous layer and central base. One re-excision with a total of 13mm safety margin and excision of muscle was necessary to achieve tumour-free margins. The patient presents quarterly to our department for aftercare with palpation and ultrasound of skin and regional lymph nodes. At the time of follow-up the patient had no event of disease for 2 years.

3.4 PATIENTS WITHDIAGNOSIS LEIOMYO-/ RHABDOMYOSARCOMA

Two patients with diagnosis leiomyosarcoma of the skin have been treated with surgery and 3D-histology at our department. The gender was for both cases male, the location upper extremity (n= 1) and lower extremity (n= 1). No distant metastasis or death of disease occurred within the study period.

No patient with diagnosis rhabdomyosarcoma of the skin has been treated at our department within the study period.

4 DISCUSSION

In recent studies of conventional histology with wide excision for the treatment of DFSP the local recurrence rates range from 10-26 % (Chang et al., 2004; Bowne et al., 2000; Gloster et al., 1996; Koh et al., 1995).^{4 7 12 18} McPeak et al.(1967) found even local recurrence rates of more than 40% in 82 patients after wide excision.⁷⁷ These high recurrence rates were reported in 1967, since then surgical techniques have been improved and recurrence rates have been decreased. However local recurrence rates with wide excision still range far over them with Mohs micrographic surgery. Chang et al.(2004) reviewed the world-wide literature and found a mean local recurrence rate of 34.3% from a total of 536 reported patients with DFSP treated with wide excision.⁴ These results suggest that the treatment with wide excision and conventional histology has diagnostic gaps and leads to higher local recurrence rates (**TABLE 8**).

Previous studies of Mohs micrographic surgery provided support for treatment of DFSP with this method. The largest study group was 58 patients, 28 of them with a follow-up period of more than 5 years and a local recurrence rate of 2% (Ratner et al., 1997).⁸ Another study of 29 patients with a follow-up period of more than 5 years showed a local recurrence rate of 0% and no regional or distant metastases (Snow et al., 2004).⁶ The highest local recurrence rate was 6.6% in 15 patients with an average follow-up period of 3 years (Gloster et al., 1996).⁷ Although no recurrences were described in most of the studies, a review of the international literature showed a mean recurrence rate of 2.4% from a total of 169 reported cases (Haycox et al., 1997).⁷⁸ However, there was a wide range in the follow-up period and patient numbers (**TABLE 8**).

Retrospective studies of adjuvant radiotherapy for the treatment of incomplete excised tumour in preventing local recurrence of DFSP have shown good results for local control. Postoperative radiotherapy results in local control rates of more than 85% in patients with positive or close surgical margins (Mendenhall et al., 2004).⁴¹ However, the exact therapeutic role still remains to be established and further long-term studies are necessary.

Molecular targeted treatment with imatinib recently became another alternative for the treatment of unresectable or partially resectable tumours, thereby possibly improving the effectiveness of surgery (McArthur, 2004).⁴² Current available clinical evidence suggests there may potentially be a role for imatinib as a first-line therapy for unresectable locally advanced or metastatic DFSP, which are extremely rare, however further investigation is needed to define the appropriate use, optimal dosage and duration of therapy with imatinib.⁴²

To our knowledge, no articles about the direct comparison of different malignant soft tissue sarcomas of the skin, especially DFSP and MFH, with surgery and long-term follow-up has been published in international literature. Our study was also done to provide information about characteristics and diversities of these tumour entities in comparison. This present study showed a preference for 3D-histology in treatment of malignant soft tissue sarcomas of the skin due to the local subclinical spreads of these tumour entities.

DFSP

This study showed very good results in management of DFSP patients with surgery and 3D-histology. In our study population only one local recurrence after 62 months and no death due to disease occurred in patients with DFSP. The 5-year recurrence free survival was 100%, 10-year recurrence free survival 96%. However 23% (21 of 91 patients with DFSP) were lost for follow-up, assuming that the real recurrence rate may be higher.

MFH

MFH lesions showed in our study population the predilection of location at the head/neck, the microscopically characteristic of a frequent horizontal cord-like or multiple growth in the depth and the surgery depth required for tumour-free margins was frequently bone/cartilage and muscle. According to this pattern, to reach a balance between surgery with finally clear margins and postoperative sufficient esthetical results is very delicate. These lesions also showed a high locally aggressive growth, tendency to metastasise and poor tumour

progression. Eight patients (27%) developed local recurrence in our study population, three died of disease and seven died due to other causes.

Patients age at the time of treatment was in 67% over 50 years and the gender in 68% male. These characteristics assume that disease detection and management is shifted in older patients with MFH lesions to a later stage when tumour extension is advanced and local control gets more difficult. Therefore an early specific surgical treatment is desirable and determining tumour progression and outcome.

The Kaplan-Meier graph for local recurrence and death free survival showed three further characteristics for MFH lesions:

1. local recurrence occurred within the first 24 months (= 2 years) and around 60 months (= 5 years)
2. beyond 72 months (= 6 years) no local recurrences were detected
3. death due to disease happened within the first 24 months(= 2 years).

These facts suggest a regular professional aftercare with awareness of high local recurrence tendency within the first five years as an important means for early tumour detection and treatment. We reached a 5-year recurrence free survival of 71% with surgery and 3D-histology which supports the preference of 3D-histology in treatment of MFH.

Liposarcoma

In our study population only 4 patients presented liposarcoma of the skin, therefore the predictable role of 3D-histology and long-term effect in treatment is limited describable and can only be evaluated in form of case reports. In three patients no local recurrence or death of disease was diagnosed within the follow-up period. In only one of four patients local recurrence occurred and lead to death due to disease. These results assume that surgery with 3D-histology may be suitable for local control of tumour spreads in treatment of liposarcomas of the skin. However late local recurrence occur and should be diagnosed as soon as possible for immediate further therapy.

Leio- and Rhabdomyosarcoma

Two patients with leiomyosarcoma no patient with rhabdomyosarcoma of the soft tissue of the skin was presented to our department within the study period. Suggesting that these tumour entities are very rare, however should be kept in mind as differential diagnosis.

Our study population showed the following features of DFSP and MFH:

DFSP patients were at the time of surgical treatment at our department at the age of 20-50 years, to equal parts male and female and the lesion location had a predilection for the trunk and upper extremities. The mean clinical tumour size was 48mm (\pm SD37) with a mean safety margin of 19mm (\pm SD12), surgery depth was in most cases the subcutis and fascia. All patients had a post-operative status of R0, one local recurrence and no death due to disease was diagnosed.

In contrast to MFH patients, which were older (> 50 years) at the time of treatment at our department, most of the patients males (68%) and the lesion location in 44% on head and neck. The mean clinical tumour size (37mm \pm SD 32) and safety margin (17mm \pm SD6) was smaller, surgery into depth frequently periosteum and cartilage. Eight patients developed local recurrence, four patients distant metastasis and three died of disease, assuming that MFH disease has a higher tendency for local recurrence and poorer progression of disease. For three patients no clear tumour margins could be achieved, and all of them had a poor tumour progression and died of tumour disease within the following two years.

Growth pattern

The analysis of the histological growth pattern supports the knowledge about microscopically extension of DFSP and MFH. Both tumours have the tendency to grow asymmetrically either sector-, cord- or multiple-like in the superficial and subcutaneous layer. This feature requires a complete histological detection because otherwise subclinical tumour spreads are failed to seize and lead to further tumour growth, metastasis and a poorer prognosis. All cases in our

study population with postoperative status of R1 showed local recurrence, metastasis and poor disease tendency. Therefore the main goal in treatment strategy must be a sensitive detection and exact excision of all residual tumour spreads.

The comparison of clinical and microscopically (clinical size plus safety margin) tumour size showed, that even small clinical lesions can have large sub clinical spreads. The processing of excision material with 3D-histology provides information about the exact geometrical tumour growth and leads to locally more specific re-excisions. Therefore healthy tissue can be spared and better esthetical results achieved.

The microscopically analysis of the geometrical growth pattern of 45 tumour excision biopsies (DFSP n= 34, MFH n= 11) showed important microscopically characteristics for DFSP and MFH tumours:

All MFH excisions showed vertically growth, more frequently in the subcutaneous layer (91%) (p= 0.019) than in the dermis layer (36%), and in 45% of the cases both vertically and in the horizontal base. This fact suggests careful surgical excision at the subcutaneous layer and the horizontal base with complete margin control due to the asymmetrical growth pattern and local aggressive tumour growth of MFH lesions.

Most of the DFSP excisions showed growth in the vertical direction (82%) and more than half of the cases no horizontal growth (59%). The lesions extended to equal parts in the dermis layer (56%) and subcutaneous layer (56%). 41% of the cases grew at the horizontal base and 24% in both vertical and horizontal direction. This fact suggests careful surgical excision at the superficial layer and also the horizontal base.

These microscopically results about the geometrical growth pattern support the importance of complete clear tumour margins as one of the most important prognostic factors of MFH and DFSP lesions.

In summary, the present study compared with studies in the international literature has shown that 3D-histology can achieve local tumour control, a reduction of excision margins and results in low local recurrence rates. Although the local recurrence rates with 3D-histology are comparable to those achieved with Mohs micrographic surgery, this method brings up further benefits in the treatment procedure. Excision material for 3D-histology is processed with the rush-paraffin technique and includes all tumour margins. Paraffin sectioning provides better slides for microscopy, smaller excision material and costs are decreased. Using the technique of complete 3D-histology the tumour extension can be geometrically located and no diagnostic gaps remain. The subclinical spreading areas can be detected very sensitively and further precise surgical excision can be performed until tumour-free margins are achieved. Surgery with 3D-histology preserves healthy tissue and achieves better esthetical results.

CONCLUSION

Surgery with 3D-histology in treatment of malignant soft tissue sarcomas of the skin resulted in low rates of local recurrence and excision margins. It is a valuable diagnostic and therapeutic means in the control of subclinical tumour spreads. Healthy tissue can be saved and therefore leads to better aesthetic surgical results. Nevertheless, further prospective studies to long-term follow-up in larger study populations are necessary to support these better results with micrographic surgery and 3D-histology.

5 Summary

BACKGROUND:

Malignant soft tissue sarcomas of the skin are rare tumour entities with a high tendency to local recurrence according to their characteristic of forming subclinical asymmetrical spreads. If these subclinical outskirts are failed to detect disease progression may result in local recurrence, metastasis and a poorer tumour prognosis. Surgery is still the principal therapeutic means in treatment of soft tissue sarcomas. Conventional surgery is based on horizontal histological evaluations, however leaves diagnostic gaps. The introduction of Mohs micrographic lead to more specific detection of subclinical spreads and following re-excisions through histological examination of serial horizontal wound margins. Breuninger et al.(1988) later introduced the technique of complete three-dimensional histology including the basis with paraffin sections which is now called 3D-histology. Surgery with 3D-histology covers all margins including the basis and therefore detects subclinical spreads very sensitively. In addition safety margins can be reduced, functionally vital tissue be preserved and better esthetical results achieved.

OBJECTIVE

Purpose of this retrospective study was to evaluate the long-term follow-up, the clinicopathological characteristics and the microscopically growth pattern of malignant soft tissue sarcomas of the skin in patients treated by surgery with 3D-histology at the department of dermatology at the University of Tübingen.

MATERIAL AND METHODS

Medical records of 131 patients with diagnosis of malignant soft tissue sarcoma of the skin that have been treated by surgery and 3D-histology at our department since 1982 have been reviewed and included. The diagnosis of malignant soft tissue sarcoma of the skin included histology of dermatofibrosarcoma protuberans (DFSP), malignant fibrous histiocytoma (MFH), liposarcoma (LS) or rhabdo-/ leiomyosarcoma.

A questionnaire to the current medical state has been mailed or in case of non response patients were questioned by phone. Data from patients treated since 1992 were collected prospectively and evaluated for the distribution of clinicopathological values.

RESULTS

The tumour histology was DFSP (91 patients), MFH (34 patients), LS (four patients) and leio-/rhabdomyosarcoma (2 patients). The group of LS was discussed in form of case reports and excluded from statistical evaluations.

The mean follow-up for DFSP was 58 months with a 5- and 10-year recurrence free survival of 100% and 96%. No metastases or death were attributed to DFSP tumour in our study population. One local recurrence occurred 62 months after treatment at our institution. These results of optimal local control for DFSP tumours with surgery and 3D-histology are comparable to those achieved with Mohs micrographic surgery published in international literature, however resulted in lower safety margins (19mm \pm SD 12) and therefore more healthy tissue could be preserved.

The mean follow-up for MFH was 62 months with a 5- and 10-year recurrence free survival of 71% and 65%. Eight patients developed local recurrence (local recurrence rate of 29%), four of them distant metastasis (lymph nodes and/ or lungs) and three died of disease. All of the three patients who died of disease had a postoperative status of R1 and diagnosis of MFH ($p= 0.001$).

In the group of LS ($n= 4$), one patient developed local recurrence 76 month after treatment and died of disease. No local recurrence was diagnosed in the remaining three patients. Two patients with leiomyosarcoma have been treated at our department. However, the predictable role of 3D-histology in treatment of these tumour entities is limited describable due to the small patient number.

The gender, age and location were a statistically significant risk factor for diagnosis with a predilection for MFH lesions in males ($p= 0.018$), age >50 years ($p= 0.002$) and head/ neck/ lower extremities ($p= 0.001$). DFSP tumours occurred in both genders equally, at the age of 20-50 years and with location on trunk/ upper extremities.

The mean clinical and microscopically tumour size was for DFSP lesions 48mm (\pm SD37)/ 67mm (\pm SD0) and for MFH lesions 37mm (\pm SD32)/ 56mm (\pm SD43). According to the location, surgery in the depth extended for MFH tumours mostly into periost/ cartilage and subcutis/ muscle, and for DFSP tumours into subcutis ($p= 0.001$).

The analysis of the histological growth of 45 tumour excisions (DFSP $n= 34$ / MFH $n= 11$) support the knowledge about the asymmetrical growth pattern with subclinical spreads and therefore the importance of precise histological tumour detection. Both tumours showed a wide spectrum of vertical (dermis/ subcutaneous layer) and/ or horizontal (subcutis/ fascia/ muscle) extension either cord-, sector- or multiple-like. MFH tumours showed all vertical growth in the dermis and subcutaneous layer, a statistically significant risk factor for the vertical growth in the subcutaneous layer ($p= 0.019$) and in 45% of the cases vertical and horizontal growth.

CONCLUSION

Surgery with 3D-histology for the treatment of malignant soft tissue sarcomas of the skin resulted in lower recurrence rates, smaller excision margins and better tumour prognosis, especially in the treatment of DFSP and MFH tumours. It is a valuable diagnostic and therapeutic means in sensitive detection of subclinical spreads and be considered as the method of choice in treatment of DFSP.

However further studies of long-term follow-up in larger study populations are necessary to support these results.

6 APPENDIX

6.1 TABLES

TABLE 4: Distribution of clinicopathological variables of 125 patients

Characteristic	No. (% of Col)				p-value
	DFSP n= 91		MFH n= 34		
Gender					0.018
Female	51	(56%)	11	(32%)	
Male	40	(44%)	23	(68%)	
Age					0.002
<10 yrs.	5	(5%)	1	(3%)	
20-50 yrs.	56	(62%)	10	(30%)	
>50 yrs.	30	(33%)	23	(67%)	
Location					0.001
Trunk	44	(48%)	6	(18%)	
Upper extremity	27	(30%)	5	(15%)	
Lower extremity	12	(13%)	8	(23%)	
Head/ Neck	8	(9%)	15	(44%)	

TABLE 5: Characteristics of surgery with 3D-histology of 84 patients

Characteristic	No. (% of Col)				p-value
	DFSP n= 66		MFH n= 18		
Presentation					0.435
Primary	54	(82%)	14	(74%)	
Recurrence	12	(18%)	4	(26%)	
No. re-excisions					0.311
0	33	(50%)	8	(44%)	
1	24	(36%)	6	(33%)	
2	7	(11%)	3	(17%)	
3	2	(3%)	0		
5	0		1	(6%)	
Clinical tumour size (mm)					
Mean (\pm SD)	48 (\pm 37)		37 (\pm 32)		
Clinical tumour size					0.468
< 20 mm	13	(20%)	6	(33%)	
20–40 mm	21	(34%)	5	(28%)	
> 40 mm	32	(48%)	7	(39%)	
Safety margin (mm)					
Mean (\pm SD)	19 (\pm 12)		17 (\pm 16)		
Maximum (mm)			60		
Microscopically tumour size (mm)					
Mean (\pm SD)	67 (\pm 40)		56 (\pm 43)		
Postoperative status					0.001
R0	66	(100%)	15	(83%)	
R1	0		3	(17%)	
Surgery into depth					0.001
Subcutis	37	(57%)	5	(28%)	
Fascia	15	(22%)	1	(6%)	
Muscle	11	(18%)	5	(28%)	
Periost/ Cartilage	3	(3%)	7	(38%)	
Unknown	25		16		

TABLE 6: Geometrical growth pattern of 45 tumour excisions

Dimension	No. (% of Col)				p-value
	DFSP n= 34		MFH n= 11		
Vertical superficial (dermis layer)					0.480
No	15	(44%)	7	(64%)	
Cord-like	2	(6%)	0		
Sector-like	9	(26%)	1	(9%)	
Multiple	8	(24%)	3	(27%)	
Vertical in the depth (subcutaneous layer)					0.019
No	15	(44%)	1	(9%)	
Cord-like	2	(6%)	4	(36%)	
Sector-like	10	(29%)	2	(18%)	
Multiple	7	(21%)	4	(36%)	
Vertical superficial and depth					0.892
No	24	(71%)	8	(73%)	
Yes	10	(29%)	3	(27%)	
Horizontal base (subcutaneous, fascia or muscle)					0.803
No	20	(59%)	6	(55%)	
Yes	14	(41%)	5	(45%)	
Vertical and horizontal					0.163
No	26	(76%)	6	(55%)	
Yes	8	(24%)	5	(45%)	

TABLE 7: Characteristics of local recurrence/ metastasis of 125 patients

Characteristic	No. (% of Col)		p-value
	DFSP n= 91	MFH n= 34	
Lost to follow-up	21 (23%)	3 (8%)	
With follow-up	n= 70	n= 31	
No. recurrence before treatment at UKT			0.590
0	51 (77%)	14 (74%)	
1	9 (14%)	4 (21%)	
2	4 (6%)	0	
>3	2 (3%)	1 (5%)	
unknown	4	12	
No. recurrences after treatment at UKT¹			0.001
0	69 (99%)	23 (73%)	
1	1 (1%)	6 (20%)	
2	0	2 (7%)	
Time to recurrence after treatment at UKT¹ Median (max./min.)(mth.)			
1 st recurrence	62	20 (65/6)	
2 nd recurrence		40 (53/27)	
Distant metastasis¹			0.002
No	70 (100%)	27 (87%)	
Yes	0	4 (13%)	
Metastasis location			
Lymph nodes		2	
Lungs		1	
Lymph nodes + lungs		1	
Survival status¹			0.001
Alive	67 (96%)	21 (68%)	
Death	3 (4%)	10 (32%)	
Cause of death			0.120
Disease	0	3 (30%)	
Other tumour	1 (33%)	0	
Other causes	2 (67%)	7 (70%)	
Follow-up			0,907
<5 yrs	46 (66%)	20 (65%)	
>5 yrs	24 (34%)	11 (35%)	

¹ within the follow-up period

TABLE 8 Studies of DFSP treated by 3D-Histology, wide excision or Mohs micrographic surgery

Study	Year	No. of patients	Follow-up (years)	No. of patients with > 5 yrs of follow-up	% of 5-yr free survival	No. of local recurrence	% of local recurrence	No. of regional or distant metastases
3D-Histology								
Current study	2005	70	1-19	24	100%	1	2	0
Breuninger et al. ²⁰	1994	23	1-12	5	100%	0	0	0
Wide excision								
Chang et al. ⁴	2003	60	1-25	–	86%	10	16,6	0
Bowne et al. ¹⁸	2000	159	4,75 (median)	–	75%	34	21	2
Gloster et al. ⁷	1996	39	3,3 (average)	–	–	4	10	1
Koh et al. ¹²	1995	19	>3	–	–	5	26	0
Mohs surgery								
Snow et al. ⁶	2004	29	5-20	29	100%	0	0	0
Ratner et al. ⁸	1997	58	–	28	–	1	2	0
Gloster et al. ⁷	1996	15	3 (average)	2	–	1	6,6	0

6.2 FIGURES

FIGURE 1:
Complete histology of three-dimensional excision margins (= 3D-histology)

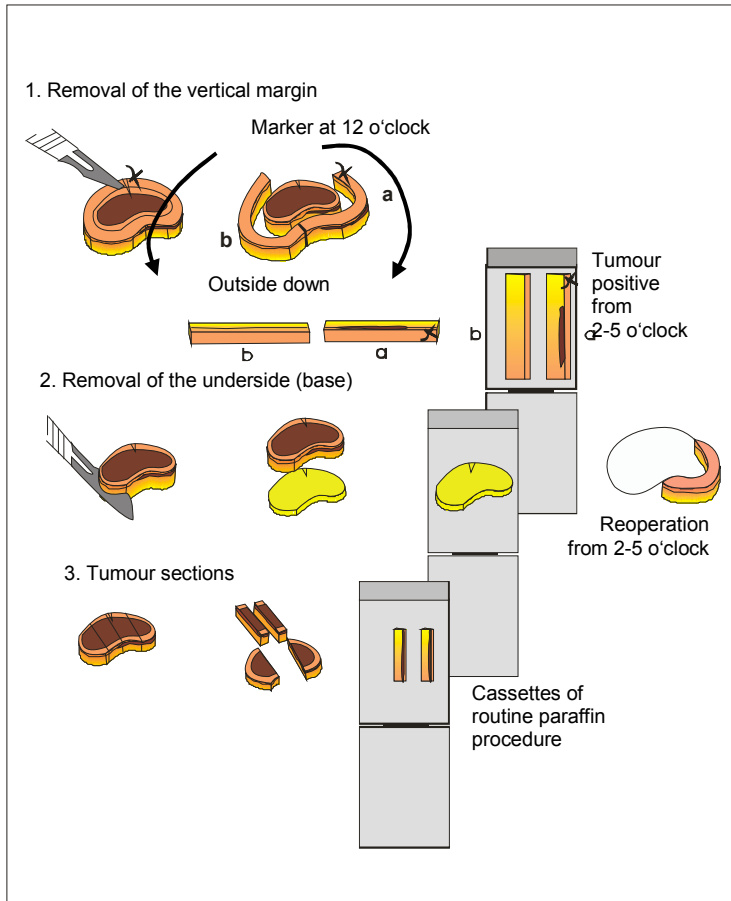


FIGURE 2- 7:

Surgical treatment with 3D-histology of a primary DFSP lesion on the back forehead in a 7-year old boy treated at our department

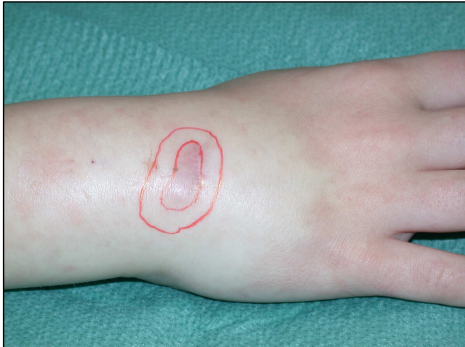

Fig.2: Clinical picture of the DFSP lesion is outlined. The planned safety margin of 7mm is labelled.

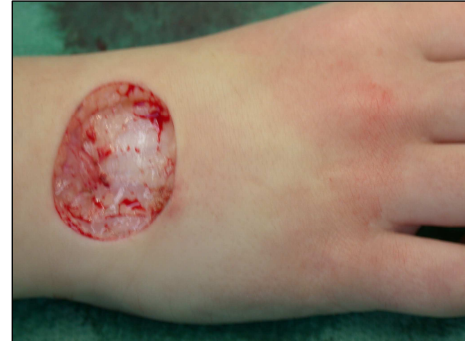

Fig.3: State after tumour excision and safety margin including the base.

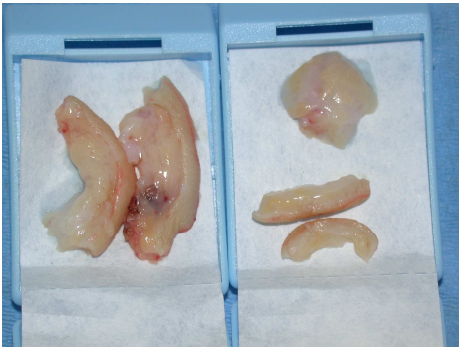


Fig.4: The complete margins of excised tissue including the base prepared for paraffin sectioning.

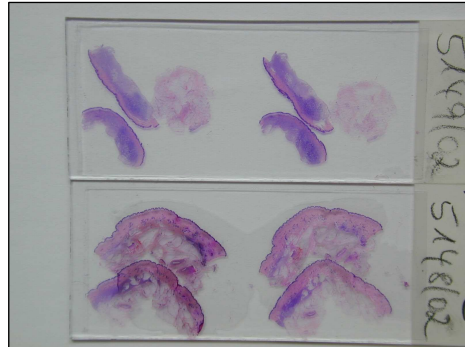


Fig.5: The specimens of the margins of figure 4. Tumour outgrowths were found at the margins 5-7 and 10-11 o'clock.

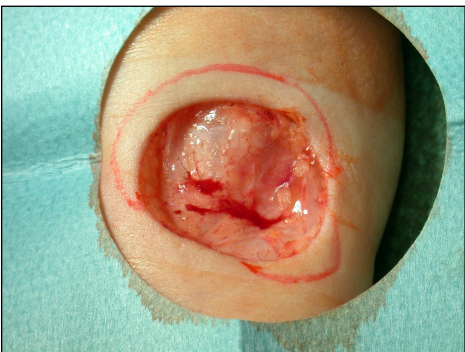


Fig.6: Re-excision was carried out at the sites of tumour margins that have been topographically localised with 3D-histology.

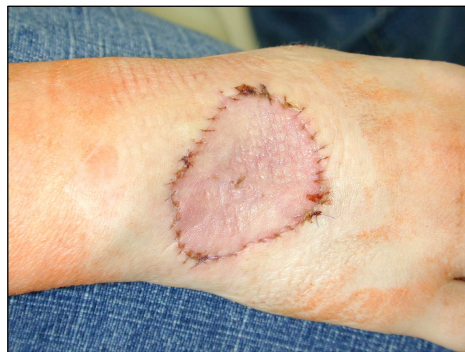

Fig.7: Wound closure with full thickness skin graft technique.

FIGURE 8: Kaplan-Meier local recurrence free survival divided by histology

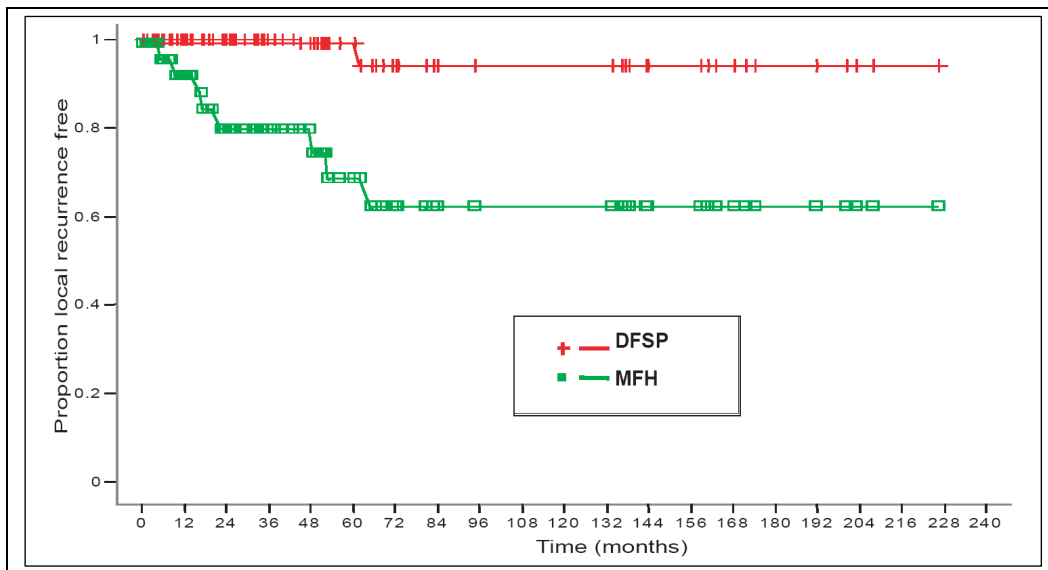
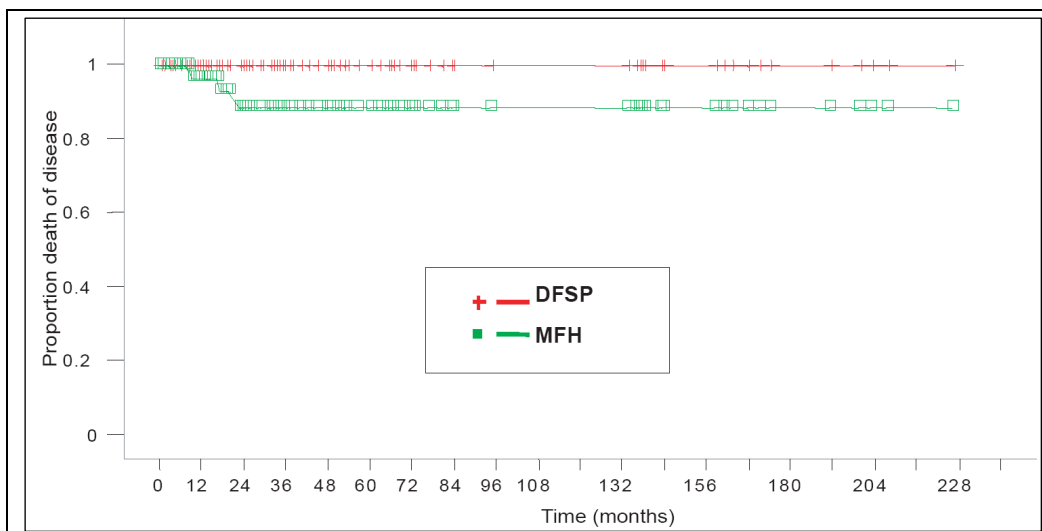


FIGURE 9: Kaplan-Meier death free survival divided by histology



6.3 QUESTIONNAIRE OF CURRENT MEDICAL STATE

FRAGEBOGEN ZUR NACHUNTERSUCHUNG IHRES HAUTTUMORS

Bitte kreuzen sie die zutreffenden Antworten an

1. Die Nachuntersuchung führt durch

- der Hautarzt
- der Hausarzt
- anderer Arzt
- Selbstuntersuchung

2. Der Hauttumor ist

- wieder aufgetreten
 - an der Operationsstelle
 - in den Lymphknoten
 - andere Hautstelle
 - anderes Organ: _____
- nicht wieder aufgetreten

3. Es wurden folgende technische Mittel benutzt

- Ultraschall der Haut
- Ultraschall der Lymphknoten
- Blutwertkontrolle
- Computertomographie
- Röntgen der Lungen
- keine, nur Tasten

4. Die Nachuntersuchung erfolgt

- vierteljährlich
- halbjährlich
- jährlich
- unregelmäßig
- gar nicht

5. Meine letzte Untersuchung war am _____.

Patient(in) ist verstorben Sterbedatum _____.

Ich möchte keine Auskunft geben

7 REFERENCES

1. Fletcher CDM, Unni KK, Mertens F (Eds.). World Health Organization Classification of Tumours. Pathology and Genetics of Tumours of Soft Tissue and Bone. IARC Press, Lyon 2002
2. Willers H, DeLaney T. Dermatofibrosarcoma protuberans: treatment options. *Curr Opin Orthop* 2004; 15: 447-51
3. Breuninger H, Schaumburg-Lever G. Control of excisional margins by conventional histopathological techniques in the treatment of skin tumours. An alternative to Mohs' technique. *Br J Pathol* 1988; 154: 167-71
4. Chang CK, Jacobs IA, Salti GI. Outcomes of surgery for dermatofibrosarcoma protuberans. *Eur J Surg Oncol* 2004; 30: 341-45
5. Mohs FE. Chemosurgery of skin cancer: Fixed tissue and fresh tissue techniques. *Arch Dermatol* 1976; 112: 211-5
6. Snow SN, Gordon EM, Larson PO, Bagheri MM, Sable DB. Dermatofibrosarcoma protuberans: a report of 29 patients treated by Mohs micrographic surgery with long-term follow-up and review of the literature. *Cancer* 2004; 101: 28-38
7. Gloster HM, Harrison KR, Roenigk RK. A comparison between Mohs micrographic surgery and wide surgical excision for the treatment of dermatofibrosarcoma protuberans. *J Am Acad Dermatol* 1996; 35: 82-87
8. Ratner D, Thomas CO, Johnson TM, Sondak Vk, Hamilton TA, Nelson BR, Swanson BR, Garcia C, Clark CE, Grande DJ. Mohs micrographic surgery for the treatment of dermatofibrosarcoma protuberans: results of a multiinstitutional series with an analysis of the extent of microscopic spread. *J Am Acad Dermatol* 1997; 37: 600-13
9. Moehrle M, Dietz K, Garbe C, Breuninger H. Conventional histology versus 3D-Histology in lentigo maligna melanoma
10. Enzinger FM, Weiss SW. Soft tissue tumors: Fibrohistocytic tumors of intermediate malignancy. St. Louis: Mosby, 1988; 14: 491-534
11. Fletcher CD, Evans BJ, MacArtney JC, Smith N, Wilson Jones E, McKee PH. Dermatofibrosarcoma protuberans: a clinicopathological and immunohistochemical study with a review of the literature. *Histopathology* 1985; 9: 921-38
12. Koh CK, Ko CB, Bury HP, Wyatt EH. Dermatofibrosarcoma protuberans. *Int J Dermatol* 1995; 34: 256-60
13. Lopes JM, Paiva ME. Dermatofibrosarcoma protuberans: A histological and ultrasctructural study of 11 cases with emphasis on the study of recurrences and histiogenesis. *Pathol Res Pract* 1991; 187: 806-13
14. Breuninger H, Sebastian G, Garbe C. Dermatofibrosarcoma protuberans- An update. *JDDG* 2004;2: 661-67
15. Smokler B. Giant cell fibroblastoma. A juvenile form of dermatofibrosarcoma protuberans. *Cancer* 1989; 64: 2154- 61

16. Mentzel T, Beham A, Katenkamp D, Die TA, Fletcher CD. Fibrosarcomatous ("high grade") dermatofibro-sarcoma protuberans: clinicopathological study of a series of 41 cases with emphasis on prognostic significances. *Am J Surg Pathol* 1998; 22: 576-87
17. Lal P, Sharma R, Mohan H, Sekhon MS. Dermatofibrosarcoma protuberans metastasizing to lymph nodes: a case report and review of the literature. *J Surg Oncol* 1999; 72: 178-80
18. Bowne WB, Antonescu CR, Leung DH, Katz SC, Hawkins WG, Woodruff JM, Brennan MF, Lewis JJ. Dermatofibrosarcoma protuberans: A clinicopathological analysis of patients treated and followed at a single institution. *Cancer* 2000; 88: 2711-20
19. Gloster HM Jr. Dermatofibrosarcoma protuberans. *J Am Acad Dermatol* 1996; 35: 355-74
20. Breuninger H, Thaller A, Schippert W. Die subklinische Ausbreitung des Dermatofibrosarkoma protuberans und daraus resultierenden Behandlungsmodalitäten. *Hautarzt* 1994; 45: 541-45
21. Kutzner H. Expression of the human progenitor cell antigen CD34 (HPCA1) distinguishes dermatofibrosarcoma protuberans from fibrous histiocytoma in formalin- fixed, paraffin- embedded tissue. *J Acad Dermatol* 1993; 28: 613-17
22. Nishio J, Iwasaki H, Ohjimi Y, Ishiguro M, Isayama T, Naito M, Iwashita A, Kikuchi M. Overrepresentation of 17q22-qter and 22q13 in dermatofibrosarcoma protuberans but not in dermatofibroma: a comparative genomic hybridization study. *Cancer Genet Cytogenet* 2002; 132: 102-8
23. Navarro M, Simon MP, Migeon C, Turc- Carel C, Pedeutour F. COL1A1- PDGFB fusion in ring chromosome 4 found in a dermatofibrosarcoma protuberans. *Genes Chromosomes Cancer* 1998; 23: 263-66
24. Simon MP, Navarro M, Roux D, Pouyssegur J. Structural and functional analysis of a chimeric protein COL1A1- PDGF gen alterations by the translocation t (17;22) (q22;q13.1) in dermatofibrosarcoma protuberans (DP). *Oncogene* 2001; 20: 2965-75
25. O'Brien KP, Seroussi E, Dal Cin P, Sciot R, Mandahl N, Fletcher JA, Turc- Carel C, Dumanski JP. Various regions within the alpha-helical domain of the COL1A1 gene are fused to the second exon of the PDGFB gene in dermatofibrosarcomas and giant- cell fibroblastomas. *Genes Chromosomes Cancer* 1998; 23: 187-93
26. Sjoblom T. Growth inhibition of dermatofibrosarcoma protuberans tumors by the platelet- derived growth factor receptor antagonist STI 571 through induction of apoptosis. *Cancer Res* 2001; 61: 5778-83
27. Sirvent N, Maire G, Pedeutour F. Genetics of dermatofibrosarcoma protuberans family of tumors: From ring chromosomes to tyrosine kinase inhibitor treatment. *Genes Chromosomes Cancer* 2003; 37: 1-19
28. Maki RG, Awan RA, Dixon RH, Jhanwar S, Antonescu CR. Differential sensitivity to imatinib of 2 patients with metastatic sarcoma arising from dermatofibrosarcoma protuberans. *Int J Cancer* 2002; 100: 623-26
29. Minter RM, Reith JD, Hochwald SN. Metastatic potential of Dermatofibrosarcoma protuberans with fibrosarcomatous change. *J Surg Oncol* 1999; 72: 178-80
30. Ah-Weng A, Marsden JR, Sanders DS, Waters R. Dermatofibrosarcoma protuberans treated by micrographic surgery. *Br J Cancer* 2002; 87: 1386-9

31. Massey RA, Tok J, Strippoli BA, Szabolocs MJ, Silvers DN, Eliezri Y. A comparison of frozen and paraffin sections in dermatofibrosarcoma protuberans. *Dermatol Surg* 1998; 24: 995-98
32. Rowsell Ar, Poole MD, Godfrey AM. Dermatofibrosarcoma protuberans: the problems of management. *Br J Plast Surg* 1986; 39: 262-64
33. Vandeweyer E, De Saint A, Gebhart M. Dermatofibrosarcoma protuberans: how wide is wide in surgical excision? *Acta Chir Belg* 2002; 102: 445-58
34. Smola MG, Soyer HP, Scharnagl E. Surgical treatment of dermatofibrosarcoma protuberans: A retrospective study of 20 cases with review of the literature. *Eur J Surg Oncol* 1991; 17: 447-53
35. Nouri K, Lodha R, Jimenez G, Robins P. Mohs micrographic surgery for dermatofibrosarcoma protuberans: University of Miami and NYU experience. *Dermatol Surg* 2002; 28: 1060-4
36. Wacker J, Khan-Durani B, Hartschuh W. Modified Mohs micrographic surgery in the therapy of dermatofibrosarcoma protuberans: analysis of 22 patients. *Ann Surg Oncol* 2004; 11: 438-44
37. Ballo MT, Zagars GK, Pisters P, Pollack A. The role of radiation therapy in the management of dermatofidrosarcoma protuberans. *Int J Radiat Oncol Biol Phys* 1998; 40: 823-27
38. Sun LM, Wang Cj, Huang CC, Leung SW, Chen HC, Fang FM, Huang EY, Lee SP. Dermatofibrosarcoma protuberans: treatment results of 35 cases. *Radiother Oncol* 2000; 57: 175-81
39. Marks LB, Suit HD, Rosenberg AE, Wood WC. Dermatofibrosarcoma protuberans treated with radiation therapy. *Int J Radiot Oncol Biol Phys* 1989; 17:379-84
40. Suit H, Spiro I, Mankin HJ, Efird J, Rosenberg AE. Radiation in management of patients with dermatofibrosarcoma protuberans. *J Clin Oncol* 1996; 14: 2365-69
41. Mendenhall WM, Zlotecki RA, Scarborough MT. Dermatofibrosarcoma protuberans. *Cancer* 2004; 101: 2503-8
42. McArthur G. Molecular targeted treatment for dermatofibrosarcoma protuberans. *Semin Oncol* 2004; 31: 30-36
43. Erlandson RA, Antonescu CR. The rise and fall of malignant fibrous histiocytoma. *Ultrasctruct Pathol* 2004; 28: 283-89
44. Randall RL, Albritton KH, Ferney BJ, Layfield L. Malignant fibrous histiocytoma of soft tissue: an abandoned diagnosis. *Am J Orthop* 2004; 33: 602-8
45. Enzinger FM, Weiss SW. Soft tissue tumors: Malignant fibrohystiocytic tumors. St. Louis: Mosby, 1988; 15: 535-66
46. Ozercan IH, Okur MI, Coskun F, Yildirim AM. Malignant fibrous histiocytoma and squamous carcinoma derived from a burn scar. *Acta Chir Belg* 2004; 104: 745-7
47. Weng WH, Wejde J,Ahlen J, Pang ST, Lui WO, Larsson C. Characterization of large chromosome markers in a malignant fibrous histiocytoma by spectral karyotyping, comparative genomic hybridization (CGH), and array CGH. *Cancer Genet Cytogenet* 2004; 150:27-32

48. Ibañ A, Coindre JM, Derre J, Mariani O, Terrier P, Ranchere D, Mairal A, Aurias A. Myxoid malignant fibrous histiocytoma and pleomorphic liposarcoma share very similar genomic imbalances. *Lab Invest* 2005; 85: 176-81
49. Gibbs JF, Huang PP, Lee RJ, McGrath B, Brooks J, McKinley B, Driscoll D, Kraybill WG. Malignant fibrous histiocytoma: an institutional review. *Cancer Invest* 2001; 19: 23-7
50. Belal A, Kandil A, Allam A, Khafaga Y, El-Husseiny G, El-Enbaby A, Memon M, Younge D, Moreau P, Gray A, Schultz H. Malignant fibrous histiocytoma: a retrospective study of 109 cases. *Am J Clin Oncol* 2002; 25: 16-22
51. Le Doussal V, Coindre JM, Leroux A, Hacene K, Terrier P, Bui NB, Bonichon F, Collin F, Mandrad AM, Contesso G. Prognostic factors for patients with localized primary malignant fibrous histiocytoma: a multicenter study of 216 patients with multivariate analysis. *Cancer* 1996; 77: 1823-30
52. Salo J, Lewis J, Woodruff JM, Leung DH, Brennan MF. Malignant fibrous histiocytoma of the extremities. *Cancer* 1999; 85: 1765-72
53. Huether MJ, Zitelli JA, Brodland DG. Mohs micrographic surgery for the treatment of spindle cell tumors of the skin. *J Am Acad Dermatol* 2001; 44: 656-9
54. Brown MD, Swanson NA. Treatment of malignant fibrous histiocytoma and atypical fibrous xanthomas with micrographic surgery. *J Dermatol Surg Oncol* 1989; 15: 1287-92
55. Schlott T, Tauber H, Fayyazi A, Schweyer S, Bartel F, Korabiowska M, Brinck U. Analysis of central regulatory pathways in p53-deficient primary cultures of malignant fibrous histiocytoma exposed to ifosamide. *Anticancer Res* 2004; 24: 3819-29
56. Fraser JA, Bratlett J. Piritrexim (ILEX Oncology). *Idrugs* 1999; 2: 1183-96
57. Kawamoto T, Akisue T, Marui T, Nakatani T, Hiltora T, Fujita I, Kursaka M, Yamamoto T. Inhibitory effect of STI571 on cell proliferation of human malignant fibrous histiocytoma cell lines. *Anticancer Res* 2004; 24: 2675-9
58. Goto T, Kosaku H, Kobayashi H, Hozumi T, Kondo T. Soft tissue sarcoma: postoperative chemotherapy. *Gan To Kagaku Ryoho* 2004; 31: 1324-30
59. Barker JL Jr, Paulino AC, Feeney S, McCulloch T, Hoffman H. Locoregional treatment for adult soft tissue sarcomas of the head and neck: an institutional review. *Cancer* 2003; 9: 49-57
60. Pollack A, Zagars GK, Goswitz MS, Pollock RA, Feid BW, Pisters PW. Preoperative vs. postoperative radiotherapy in the treatment of soft tissue sarcomas: a matter of presentation. *Int J Radiat Oncol Biol Phys* 1998; 42: 563-72
61. Ballo MT, Zagars GK, Cornier JN, Hunt KK, Feig BW, Patel SR, Pisters PW. Interval between surgery and radiotherapy: effect on local control of soft tissue sarcoma. *Int J Radiat Oncol Biol Phys* 2004; 58: 1461-7
62. Enzinger FM, Weiss SW. *Soft tissue tumors: Liposarcoma*. St. Louis: Mosby, 1988; 17: 641-93
63. Endo H, Hirokawa M, Ishimaru N, Tanaka Y, Yamashita M, Sakaki M, Hayashi Y, Sano T. Unique cell membrane expression of topoisomerase-II alpha as a useful diagnostic marker of liposarcoma. *Pathol Int* 2004; 54: 145-50

64. Weitz, Antonescu CR, Brennan MF. Localized extremity soft tissue sarcoma: improved knowledge with unchanged survival over time. *J Clin Oncol* 2003; 21: 2719-25
65. Evans HL. Liposarcomas and atypical lipomatous tumors: a study of 66 cases followed for a minimum of 10 years. *Surg Pathol* 1988; 1:41
66. Kilpatrick SE, Doyon J, Choong PF, Sim FH, Nascimento AG. The clinicopathologic spectrum of myxoid and round cell liposarcoma. A study of 95 cases. *Cancer* 1996; 77:1450-8
67. Espat NJ, Bilsky M, Lewis JJ, Leung D, Brennan MF. Soft tissue sarcoma brain metastases. Prevalence in a cohort of 3829 patients. *Cancer* 2002; 94: 2706-11
68. Lehnhardt M, Kuhnen C, Drucke D, Homann HH, Joneidi Jafari H, Steinau HU. Liposarcoma of the extremities: recent developments in surgical therapy: analysis of 167 patients. *Chirurg* 2004; 75: 1182-90
69. Kaspar B, Lehnert T, Bernd L, Mechtersheimer G, Goldschmidt H, Ho AD, Egerer G. High-dose chemotherapy with autologous peripheral blood stem cell transplantation for bone and soft-tissue sarcomas. *Bone Marrow Transplant* 2004; 34:37-41
70. Hartmann JT, Patel S. Recent developments in salvage chemotherapy for with metastatic soft tissue sarcoma. *Drugs* 2005; 65: 167-78
71. Moureau-Zabotto L, Thomas L, Bui BN, Chevreau C, Srockle E, Martel P, Bonneville P, Marques B, Coindre JM, Kantor G, Matsuda T, Delannes M. Management of soft tissue sarcomas (STS) in first isolated local recurrence: retrospective study of 83 cases. *Radiother Oncol* 2004; 73: 313-9
72. Pitson G, Robinson P, Wilke D, Kandel RA, White L, Griffin AM, Bell RS, Catton CN, Wunder JS, O'Sullivan B. Radiation response: an additional unique signature of myxoid liposarcoma. *Int J Radiat Oncol Biol Phys* 2004; 60: 522-6
73. Karasek K, Constine LS, Rosiers R. Sarcoma therapy: functional outcome and relationship to treatment parameters. *Int J Radiat Oncol Biol Phys* 1992; 24: 651-6
74. Breuninger H, Schimek F, Heeg P. Subcutaneous infusion anesthesia with diluted mixtures of prilocain and ropvacain. *Langenbecks Arch Surg* 2000; 385:284-9
75. DuBay D, Cimmino V, Lowe L, Johnson TM, Sondak VK Low recurrence rate after surgery for dermatofibrosarcoma protuberans: a multidisciplinary approach from a single institution. *Cancer* 2004; 100(5): 1008-16
76. Kaplan EL, Meier P. Nonparametric estimation from incomplete observation. *J AM Stat Assoc* 1958; 53: 457-62
77. McPeak CJ, Cruz T, Nicastrì AD. Dermatofibrosarcoma protuberans: an analysis of 86 cases-five with metastasis. *Ann Surg* 1967; 166: 803-16
78. Haycox CL, Odland PB, Olbricht SM, Casey B. *Ann Plast Surg* 1997; 38. 246-51

Danke...

... ganz besonders an meinen Doktorvater Herrn Professor Dr. H. Breuninger (Universitätsklinik Tübingen, operative Dermatologie) für die Überlassung des interessanten Themas und Krankengutes dieser Dissertation, die Betreuung und Unterstützung bei auftretenden Fragen und Problemen

... an Frau Doris Guénon vom Institut für medizinische Informationsverarbeitung der Universität Tübingen für die hilfsbereite Einführung in die Arbeit mit dem Statistikprogramm JMP® software version 5.1 und freundliche Unterstützung bei auftretenden Fragen und Problemen bei der statistischen Auswertung

... an Herrn Dr. Blumenstock vom Institut für medizinische Informationsverarbeitung der Universität Tübingen für die freundliche Beratung zur statistischen Auswertung und Unterstützung bei auftretenden Fragen

...an Frau Elisabeth Merkle für die freundliche und stete Unterstützung bei allen auftretenden organisatorischen und formalen Fragen

...an meine lieben Eltern für die fortwährende Unterstützung

...und nicht zuletzt an alle meine lieben Freunde

CURRICULUM VITAE

PERSÖNLICHE ANGABEN

Geburtsdatum	21.03.1975
Geburtsort	Böblingen
Staatsangehörigkeit	deutsch

SCHULISCHE AUSBILDUNG

1982- 1985	Grundschule, Musberg
1986- 1994	Immanuel Kant Gymnasium, Leinfelden
Juni 1994	Abitur

BERUFSAUSBILDUNG

	Ausbildung zur Med.-techn.- Laborassistentin
10/1994- 10/1997	Katharinenhospital, Stuttgart

UNIVERSITÄRE AUSBILDUNG

	Studium der Humanmedizin
10/1997- 09/1999	Friedrich Schiller Universität, Jena
September 1999	Ärztliche Vorprüfung
10/1999- 11/2004	Eberhard Karls Universität, Tübingen
März 2001	1. Staatsexamen
April 2003	2. Staatsexamen
10/2003- 09/2004	Praktisches Jahr <i>Innere Medizin</i> Kreis Krankenhaus Sigmaringen <i>Chirurgie</i> Ospedale S.Chiera Università degli studi di Pisa, Italien <i>Anästhesie (Wahlfach)</i> Toronto East General Hospital, Kanada
24.11.2004	3. Staatsexamen (Ärztliche Prüfung) Kreis Krankenhaus Sigmaringen
08.12.2004	Approbation als Ärztin