

**Value of Endoscopy of the Internal Auditory Canal for
Microsurgery of Intracanalicular Vestibular
Schwannoma**

**Inaugural-Dissertation
zur Erlangung des Doktorgrades
der Medizin**

**der Medizinischen Fakultät
der Eberhard Karls Universität
zu Tübingen**

**Vorgelegt von
Shiwei Song**

2014

Dekan: Professor Dr. I. B. Autenrieth

1. Berichterstatter: Professor Dr. M. Tatagiba

2. Berichterstatter: Professor Dr. H. Löwenheim

INDEX

Abbreviation list	2
Figure list	4
Table list	5
Introduction	6
1 <i>Intracanalicular vestibular schwannoma (IVS)</i>	7
2 <i>Anatomical remarks of IAC in IVS surgery</i>	14
3 <i>Endoscopic techniques in neurosurgery</i>	19
Patients and Methods	26
1 <i>Patients</i>	26
2 <i>Endoscopic instruments</i>	29
3 <i>Surgical procedures</i>	29
Results	32
Discussion	38
1 <i>Intracanalicular vestibular schwannoma (IVS) surgery</i>	38
2 <i>Practical experiences of endoscopes in IVS surgery</i>	39
3 <i>Facial nerve function preservation</i>	42
4 <i>Hearing preservation in IVS endoscope-assisted surgery</i>	43
5 <i>Completeness of IVS removal with endoscopic assistance</i>	45
6 <i>Postoperative complications in endoscope-assisted IVS surgery</i>	45
Conclusion	47
References	48
Abstract	56
Zusammenfassung	57
Acknowledgment	59
Curriculum vitae	60

Abbreviation list

AEP	Auditory evoked potential
BAEP	Brainstem auditory evoked potential
CMAP	Compound muscle action potential
CNAP	Cochlear nerve auditory evoked potential
CPA	Cerebellopontine angle
CSF	Cerebrospinal fluid
CT	Computed tomography
EAM	Endoscope-assisted microneurosurgery
ECM	Endoscope-controlled microneurosurgery
EI	Endoscopic inspection
EMG	Electromyography
EN	Endoscopic neurosurgery
ETV	Endoscopic third ventriculostomy
FMAP	Facial muscle action potential
GKR	Gamma-knife radiosurgery
IAC	Internal auditory canal
ICaP	Intracanalicular pressure
IVS	Intracanalicular vestibular schwannoma
IVSs	Intracanalicular vestibular schwannomas
MRI	Magnetic resonance imaging
NF2	Neurofibromatosis type 2
PTA	Pure tone average

REZ	Root exit zone
SDS	Speech discrimination score
S-F line	Sigmoid-fundus line

Figure list

Figure 1: The Tübingen line	16
Figure 2: CT bone window depicting dangerous anatomical structures	17
Figure 3: Sigmoid-fundus line (S-F line) in Case 4	18
Figure 4: CT bone window depicting well-pneumatized temporal bone	19
Figure 5: Endoscopic instruments (Karl Storz, Tuttlingen, Germany)	29
Figure 6: Surgical procedures in endoscope-assisted microneurosurgery	31
Figure 7: Preoperative and postoperative CT bone window	35
Figure 8: Preoperative and postoperative gadolinium-enhanced MRI	36
Figure 9: Microscopy in intracanalicular vestibular schwannoma surgery	37
Figure 10: Endoscopy in intracanalicular vestibular schwannoma surgery	37

Table list

Table 1: Hopf classification of endoscopic techniques in neurosurgery	21
Table 2: Hannover vestibular schwannoma classification grade	26
Table 3: House-Brackman classification grade	28
Table 4: Gardner–Robertson’s hearing classification	28
Table 5: Clinical features in 24 IVS patients with endoscope-assisted microneurosurgery	34
Table 6: Pre- and postoperative cranial nerves function and completeness of tumor removal in 16 patients with at least 6 months follow-up	35

Introduction

Vestibular schwannomas are benign tumors that arise from Schwann cells of the vestibular nerve within the internal auditory canal (IAC) and extend into the cerebellopontine angle (CPA). In recent years, radical tumor removal and functional preservation of cranial nerves represent the ideal treatment option for vestibular schwannomas [2, 82, 83]. In addition, the diagnosis of vestibular schwannomas has changed considerably as the sensitivity of magnetic resonance imaging (MRI) has increased. Nowadays, surgeons are more often dealing with small tumors, especially intracanalicular vestibular schwannomas (IVSs). However, because of the anatomic limitation in the exposure of IAC for the retrosigmoid approach, complete removal of intracanalicular vestibular schwannoma (IVS) would lead to the familiar risk of postoperative complications, such as facial paresis, hearing loss, cerebrospinal fluid (CSF) leak and meningitis [35, 57, 101].

The introduction of new medical technology promises improved surgical outcomes and better treatment options in many clinical conditions. As a notable example in today's new trends in minimal invasive surgery, endoscopy is a main tool to visualize the interior of the human body or the surgical scene. Endoscopes offer better visibility during operations and enable surgeons to inspect important anatomic structures with less invasions [6, 24, 38]. The potential usefulness of endoscopy in IVS surgery lies in its likely ability to visualize the blind area of IAC beyond the limit of the microscopic view.

This retrospective study aims to investigate the feasibility and efficiency of endoscopy of IAC for microsurgery of IVS by using standard microsurgical instruments available in most hospitals and applying principles of the retrosigmoid approach

1 Intracanalicular vestibular schwannoma (IVS)

1.1 Clinical features of IVS

Since Rudolf Carl Virchow first defined neuroglia as the cells comprising the connective tissue of the nervous system in 1846, vestibular schwannoma tumors have had many names. With later advances in microscopy, the Schwann cell was correctly identified as the cell of tumor origin, and the vestibular portion of the vestibulocochlear cranial nerve was established as its predominant location of occurrence. Vestibular schwannomas are slow-growing tumors that arise from the superior or inferior vestibular nerve, usually initiating at the junction between the peripheral and the central myelin sheath. The junction is known as the Obersteiner-Redlich zone and often occurs near the vestibular ganglion although its location can vary [4]. Vestibular schwannomas occur either as bilateral tumors, or as sporadic unilateral tumors. Bilateral vestibular schwannomas are associated with a hereditary disorder known as neurofibromatosis type 2 (NF2) and are regarded as pathologically distinct from the sporadic form. Unilateral tumors constitute 95% of vestibular schwannomas while bilateral tumors constitute only 5% of vestibular schwannomas [95].

The reported incidence of new vestibular schwannomas was estimated from 9 to 25 per million per year [63, 104]. IVS had been documented at a 0.32% rate in a total of 615 consecutively diagnosed vestibular schwannomas [103]. However, Samii et al. demonstrated 16 (2.7%) IVSs in 600 patients with consecutive vestibular schwannoma cases operated [85]. Many factors, including most notably auditory brainstem response tests, well-informed imaging techniques such as MRI with gadolinium DTPA and contrast-enhanced computed tomography (CT), as well as an informed population and high degree of doctors' suspicious in patients with unilateral

symptoms, have contributed to the increasing numbers of newly diagnosed intracanalicular tumors.

Symptoms of vestibular schwannoma are highly variable. They include unilateral sensorineural hearing loss, tinnitus, pressure in the ear, otalgia, and occasionally vertigo, which result from pressure exerted by the tumor upon the cochlear and vestibular portions of the eighth cranial nerve. Other late symptoms include ataxia, diplopia, dysphagia, hemiparesis, increased intra-cranial pressure and cerebellar hemisphere syndrome [94, 96]. Contrary to large tumors, IVS commonly represent no impending complication or minimal symptoms, if any, which would prompt treatment. These small tumors do not cause brainstem or severely adjacent cranial nerve compression unless significant growth occurs. The only reasonable cause for treatment is attempted hearing preservation. Large tumors may cause only little auditory dysfunction, while small tumors are likely to lead to severe hearing loss. After evaluating 42 patients with vestibular schwannoma by tumor size, location and clinical presentation, Lapsiwala et al. reported that patients with tumors in the IAC experienced more early subjective hearing loss than those harboring tumors in the CPA [8]. Coincidentally, the study of Samii et al. also proved that clinical presentation of IVS is markedly different from other vestibular schwannomas [85]. In his 16 out of 600 vestibular neuromas, patients with IVS have more severe hearing loss than others, which shortened diagnosis time. In a study on the hearing function in 156 patients with purely IVS, Caye-Thomasen et al. reported that the mean pure tone average (PTA) on the tumor ear was 51 dB and the mean speech discrimination score (SDS) is 60% at diagnosis, compared with 20 dB and 96% on the contralateral ear. In addition, during the mean 4.6 years following observation of these tumors, the hearing loss progressed faster than in the contralateral healthy ear [14]. The pathogenesis of auditory dysfunction in patients with IVS is presumptive complexity. However, the difference between profound hearing loss in a patient

with a small IVS and normal hearing in a patient with only a CPA tumor may be explained by the differences in their intracanalicular pressure (ICaP). Lapsiwala et al. documented the measurement results of ICaP in patients with vestibular schwannoma and indicated a notable elevation in ICaP in some patients undergoing vestibular schwannoma surgery [51]. Meanwhile, the relation between pressure in the IAC and preoperative hearing or auditory evoked potential (AEP) recordings indicated that elevation in the ICaP was correlated with auditory dysfunction in these patients. High ICaP within IAC may lead to the change of labyrinthine artery blood supply and local CSF micro- environment or a direct pressure injury to the cochlea, which may cause ischemia of the auditory apparatus resulting in hearing loss.

1.2 Management of IVS

Early diagnosis of IVS raised the debate of whether or not treatment is required and which treatment is best suited for these small neoplasms. So far, there are three treatment options for patients with IVS: observation, radiotherapy and microsurgery. The selection of a management option is associated with the factors such as the patient's age, tumor size, hearing status, occupation, and the patient's desire for the cranial nerve's function preservation and patient's preference after honest and accurate informed consent.

In regard to the management of IVS, conservative management may be adopted for several situations as follows: patients with asymptomatic vestibular schwannoma, patients in whom the only hearing ear is involved, elderly patients with mild symptoms, or patients refusing any treatment [79]. The theoretical foundation of conservative management was supported by two main principles: preservation of an asymmetrical or minimally symptomatic period and avoidance of treatment complications and side-effects. Therefore,

studies on the natural history of IVS should be considered. It has been postulated for many years that IVS belongs to a distinct category of vestibular schwannoma that displays an original biological behavior [78]. However, the reported percentage of sporadic IVS suggested that the possibility of tumor growth was widely variable, ranging from 29% to 85% [11, 14, 16, 79, 92]. Different growth rates in these studies were attributed to many methodological pitfalls, such as different and insufficient follow-up periods, limited number of enrolled patients and selection bias for enrolled patients. For instance, a series of 123 patients with 127 vestibular schwannoma tumors were selected for the wait and scan strategy during the period from 1973 to 1999 [15]. They were evaluated by three stages of growth results. The results from 1973 revealed tumor growth in 74% of the patients, no growth in 18% of the patients and shrinkage in 8% of the patients. By 1996, the results changed to tumor growth in 82% of the patients, no growth in 12% of the patients and shrinkage in 6% of the patients. By 1999, tumor growth was detected in 85% of the patients, no growth in 9% of the patients and shrinkage in 6% of the patients. This research suggests that tumor growth is time dependent and most tumors ultimately grow over 10~20years.

On the other hand, attempting to preserve hearing function has played an important role in the choice of today's management option of IVS. Hearing decline occurs in a significant percentage of patients with IVS even in the group of stable IVS patients. In the meantime, the chance of having hearing loss appears greater for patients with fast growth tumors. Studies on conservative management with IVS indicated that the hearing decrease rate ranged from 37.5 to 70% [11, 21, 77, 79]. There have been many studies on the predictors of hearing function with IVS and most of them focused on initial hearing level and tumor growth [14, 92, 93, 97]. Caye-Thomassen evaluated 156 patients with IVS and demonstrated that the initial mean PTA was 51 dB and the initial mean SDS was 60%. During the 4.6 years follow-up, the risk of a

significant subsequent hearing loss (≥ 10 dB PTA or $\leq 10\%$ SDS) was 54%. PTA deterioration rate was associated with the mean absolute growth rate, but showed no relation with the initial size of tumor or tumor sublocalization [14]. In the study of Roche et al., 5 of the 16 patients (31.2%) with initial near normal hearing (defined as PTA ≤ 30 dB and SDS $\geq 70\%$) experienced deteriorated hearing levels (defined as PTA exceeded 10 dB) after the mean 34.2 months follow-up period [79]. However, they reported that tumor growth was not statistically correlated with hearing preservation. In order to achieve successful conservative management, rigorous follow-ups and a patient's willingness and compliance are essential. If hearing preservation is a main goal in the treatment of patients with IVS, early radiotherapy and microsurgery should be considered.

Radiotherapy was first proven to be an effective and safe option to manage vestibular schwannoma by Lars Leksell in 1972 [69]. Since then, many studies have also confirmed his finding [65, 66, 69, 78]. The similar therapeutic options include stereotactic radiosurgery, stereotactic or conventional fractionated radiation treatments, and proton beam therapy. Currently, radiotherapy is an ideal alternative to microsurgical removal of small vestibular schwannomas. The primary goal of radiotherapy is control of tumor growth. Nowadays physicians can confidently advise patients that all forms of radiotherapy will arrest tumor growth, ranging from 90% to 100% [46, 61, 62, 75]. Advances in high-resolution MRI, treatment planning computer software and robotics have shifted the focus from only the control of tumor growth towards also quality of life for subjects such as good facial outcomes and preservation of useful hearing with vestibular schwannoma radiotherapy. Vermeulen et al. presumed that patients with IVS represented a special subset complication after gamma-knife radiosurgery (GKR), especially when the cochlear nerve was most likely predisposed to injury [107]. Radiation energy could compromise cochlear nerve fibers inside the IAC, resulting in hearing

deterioration after radiation therapy. However, modern treatment techniques enable physicians to measure more precise dose on the tumor volume. According to the most recent literatures, the dose delivered to the tumor margin has been progressively decreased to 12Gy, which offered a higher tumor control rate and a lower cranial nerve injury rate [62]. To analyze the relationship between radiation dose and audiologic measurement results following GKR, Massager et al. found that the accumulated dose of radiation prescribed to IAC was statistically associated with patients' hearing outcomes [56]. For this reason, fractionated radiosurgical treatment or proton beam radiosurgery might provide new options to improve hearing preservation which have been reported by some literature. Niranjana et al. demonstrated a statistically significant relation between hearing preservation following GKR and small tumor diameter by evaluating the GKR treatment of 15 patients with purely IVS [64]. Bassim et al. conducted a meta-analysis of 56 recent literatures with vestibular schwannoma radiotherapy and concluded that there was a significant correlation between the length of reported follow-up and both the number of patients requiring further treatment (positive correlation) and the rate of hearing preservation (negative correlation) [5].

Radiation therapy has no ability to radically remove tumors therefore it is hard to compare with microsurgery. In the meantime, radiation exposure inherits a small risk of secondary malignancy. According to some literatures, follow-up time was likely too short to assess the true risk of patients with IVS [5]. Recommendations for use of radiation as the primary treatment modality should be made with caution especially when facing young patients or patients with NF2. And keep in mind that salvage surgery after failed radiation carries increased risks to the facial nerve and virtually no chance of hearing preservation.

Since ICaP plays a role in hearing loss in patients with IVS, as previously discussed, undergoing an early surgical excision of small tumors will be an option to avoid cochlear injury and hearing deterioration. IVS is not a life-threatening disease. Thus, the goal of microsurgery in IVS is preservation of neurological function, especially hearing level and facial nerve function, with radical tumor removal, to improve the quality of life. Furthermore, with improving microsurgical techniques and neurosurgeons' dexterity with vestibular schwannoma microsurgery, neurosurgeons can achieve the goal of performing IVS surgery at a higher level. Supporters of microsurgery treatment also believe that early proactive surgical procedure can be easier and safer [67].

Recent advances in intraoperative neurophysiological monitoring have emerged as an essential part of vestibular schwannoma surgery, which significantly decreased the likelihood of functional impairment of the facial nerve and cochlear nerve. Constant facial nerve EMG helps to identify the nerve anatomically, while also helping to preserve the functional integrity. In response to direct intracranial electrical stimulation, compound muscle action potential (CMAP) is capable of further assessing facial nerve integrity. By utilizing the corticobulbar pathway for facial nerve monitoring, facial muscle action potential (FMAP) can achieve the accessibility to evaluate the function of the facial nerve during the surgery, as well as predicting facial nerve outcome with high accuracy. These three neuromonitoring techniques contribute to a high facial function preservation rate, ranging from 94%~100%, reported by most literatures on IVS [68, 70, 98]. During the surgery, cochlear nerve function can be monitored by brainstem auditory evoked potentials (BAEP) and cochlear nerve auditory evoked potentials (CNAP). These modalities of evoked potential are not affected by commonly used anesthetics. In operations to remove IVS, these techniques would be helpful if surgeons were suspended at the time that intraoperative monitoring waves changed

either latency or amplitude. Recording of BAEP may be supplemented by recording CNAP from the exposed cochlear nerve. However, ischemia affecting the cochlea nerve by injury to the labyrinthine artery could lead to delayed hearing loss, regardless of preserved CNAP or BAEP [91].

Three surgical approaches commonly used to remove vestibular schwannoma are: the translabyrinthine, middle fossa, and retrosigmoid. The choice of approach depends on different medical jurisdictions and different therapeutic centres, influenced in part by available expertise and equipment. Considering hearing function preservation with IVS surgery, middle fossa and retrosigmoid approach were compared in some articles, where some of the advantages and disadvantages of each approach were described [19, 67, 68, 80]. Compared to middle fossa approach, neurosurgeons are more familiar with the retrosigmoid approach which brought similar results for hearing preservation and superior results for facial nerve function [68]. The main problem with retrosigmoid approach is that the tumor cannot be removed from the lateral end of IAC under the microscopic control alone as a result of the complexity of the neighbouring anatomical structure of IAC. With concerns of injury to bony labyrinth, the whole IAC cannot be open. Thus, the blind manipulation at the fundus of IAC led to postoperative sequelae such as residual tumor, CSF leak, and cranial nerve dysfunction, including hearing loss and facial weakness [80, 101].

2 Anatomical remarks of IAC in IVS surgery

A clear knowledge of the IAC anatomy would facilitate a more efficient surgical approach to remove IVS. The IAC is a tubular bony excavation that transmits the facial nerve, vestibular, cochlear nerves, intermedius nervus, and the labyrinthine artery and vein from the posterior fossa into the petrous bone. The canal has an anterior wall, posterior wall, roof, floor, porus (the medial border)

and fundus (the lateral end). This opening porus is in oval shape. Two bony crests, the transverse and vertical crests (Bill's bar), subdivided the fundus of the IAC into three compartments. The upper and lower compartments are separated by the transverse crest. The upper compartment is further split into an anterior and a posterior compartment by the vertical crest.

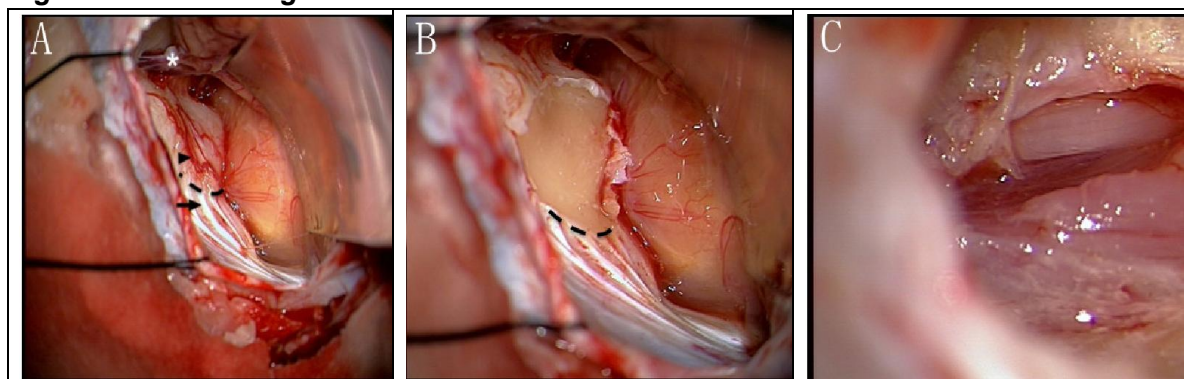
Individuals present a variety of appearances of the facial and vestibulocochlear nerves but follow certain consistent patterns in the IAC [48]. In general, the facial nerve remains superior and anterior to the vestibulocochlear nerve or its branches and maintains its tubular shape throughout its course in the canal. The vestibulocochlear nerve occupies the posterior inferior portion of the canal. Many studies demonstrated that the vestibulocochlear nerve divided into individual nerves only in the most lateral aspect of the IAC [48, 81]. Rubinstein et al.'s study based on cadaver dissection, CT and MRI findings, indicated that the cochlear and vestibular nerves usually separated approximately 3 to 4 mm from the lateral end of the IAC, and the vestibular nerve divided into the inferior and superior vestibular nerves a millimeter or two from the crest at the lateral end of the canal [81]. At the fundus, the facial nerve is located in the anterior and superior compartment. In the anteroinferior compartment is the cochlear nerve. The posterior compartment is occupied by vestibular nerves, which are named superior or inferior vestibular nerves based on their relative position.

A varied amount of fibrous tissue was identified between the individual nerves in the IAC, especially in the middle and lateral part. In the study of Ozdogmus et al., scanning electron microscopic evaluations showed that some vestibular nerve bundles may build the connections with the facial and/or cochlear nerves, but no facial-cochlear connections were found [71]. The presence of anastomotic connections may be the cause of the vestibular disturbance in facial paralysis and the persistence of tinnitus after cochlear neurectomy.

These connections also may be the reason for the rare incidence rate of cochlear schwannoma and facial schwannoma in IAC. Connecting branches between the nerve bundles of the IAC need to be prudently managed under higher magnification and illumination in the lateral end of IAC to avoid unexpected disturbances.

Drilling of the posterior wall to the lateral portion of the canal is essential for neurosurgeons to achieve an unobstructed view of the tumor at its lateral end for sharp dissection of the tumor and to identify the cochlear and vestibular nerves at the most lateral part of the canal. Our department utilized the Tübingen line as a landmark to initially navigate the IAC in 900 consecutive patients with vestibular schwannomas since 2004 (**Figure 1**). The Tübingen line connects the ending points of the dural folds covering the area involved between the jugular foramen and the medial part of the sigmoid sinus inferiorly and extending for 5 to 7 mm [12]. Drilling the posterior wall of IAC was initiated from 3 to 5 mm above the line. The Tübingen line is a convenient and safe modality to initially navigate the IAC and start the drilling in the appropriate area.

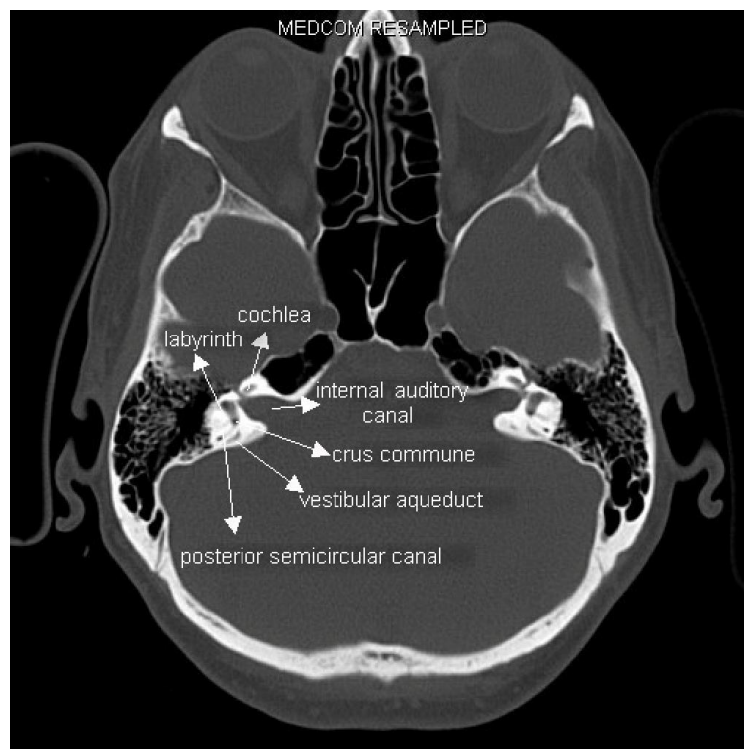
Figure 1: The Tübingen line



A: The Tübingen line delineated by black dotted line was exposed after cerebellar retraction. B: The covering dura was removed under the guide of the Tübingen line. C: Internal auditory canal was opened after drilling the posterior wall.

However, the posterior semicircular canal and its common crus are located just lateral to the posterior wall of IAC (**Figure 2**). The vestibular aqueduct and the endolymphatic sac are situated inferolateral to the posterior wall. Injuries to the labyrinth, such as the mixture of blood and bone dust with perilymph fluid and inflammatory reactions of the inner ear, will cause severe hearing deterioration and vertigo [102]. For IAC, the neurosurgeon has to open the IAC by drilling from the porus to the fundus for efficient tumor removal with an important objective of hearing preservation. Thus, the neurosurgeon must remove bone cautiously to avoid damaging labyrinthine structures.

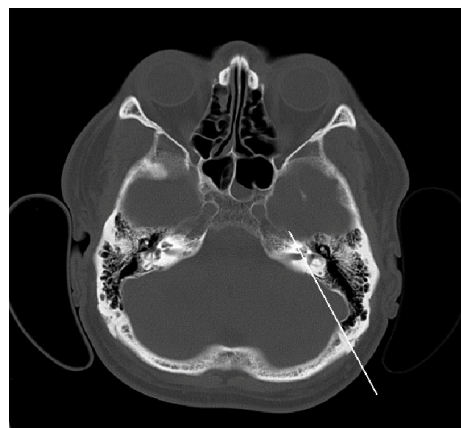Figure 2: CT bone window depicting dangerous anatomical structures while drilling IAC in case 2



So far no notable anatomical landmarks can navigate the location of the posterior semicircular canal and the crus commune to avoid damage. Individual views on how far laterally the IAC may be opened without violating labyrinthine integrity are substantially diverse [10, 57, 110]. Some studies have demonstrated that drilling of the medial 80% to 90% of the IAC is available via

the retrosigmoid approach, and the lateral 2 mm of the IAC needs to remain with tumors filling the entire canal [102]. Blevins et al. suggested that a mean of 3.0 mm (32% of the IAC length) must remain to obviate labyrinthine injury, with a range between 1.1 mm and 5.3 mm (9% to 58% of the IAC), based on his evaluation on the exposure of the lateral limitation of the IAC via the retrosigmoid approach [10]. Different surgical positions led to different data outcomes. At the same time, each additional 1 cm retraction on the cerebellum provided approximately 1 mm further exposure of the canal [10]. Tatagiba et al. and Yokoyama et al. introduced the sigmoid-fundus line (S-F line), an imaginary line from the medial side of the sigmoid sinus to the fundus of the internal auditory canal, to evaluate the potential risk of injury to the labyrinth via the retrosigmoid approach (**Figure 3**) [102, 110]. S-F line is also known as the “safe lateral line”. High-resolution preoperative thin-section CT demonstrated whether the crus commune and the posterior semicircular canal lie medially or laterally in connection with S-F line. Considering the risk of compromising the labyrinth, if the structures were medial to or on the S-F line, in our department, we remained 4~5 mm of the posterior wall of IAC by drilling. Therefore, it was essential to obtain visual access to the inside content of the IAC by introducing a new surgical instrument, providing a view from obstructed region.

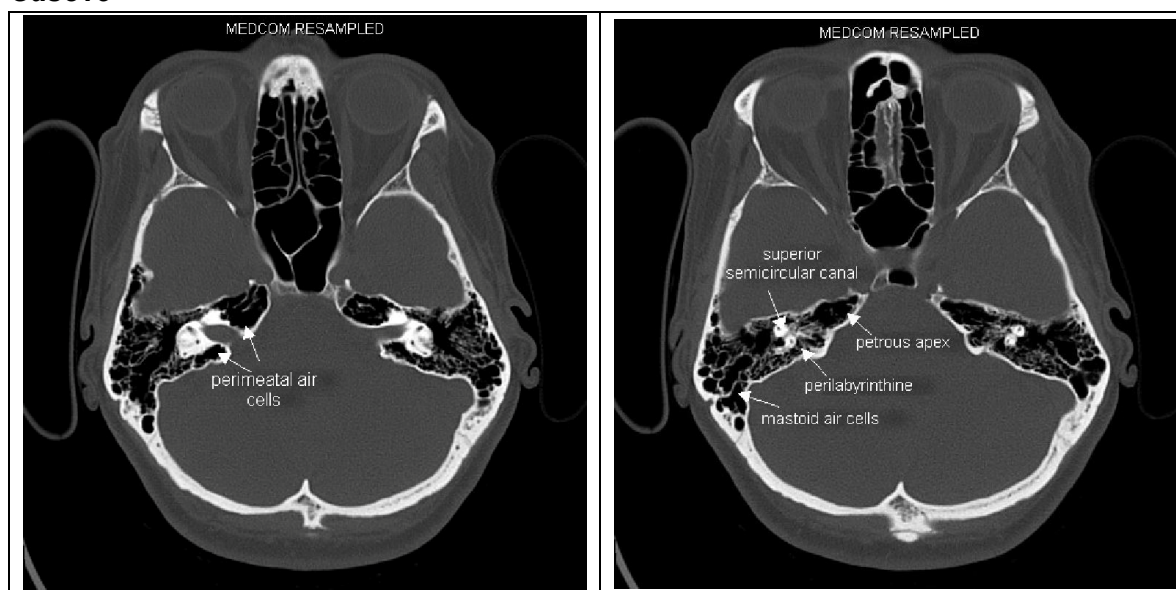
Figure 3: *Sigmoid-fundus line (S-F line) in Case 4*



CT bone window of Case 4 (right sight T1 tumor) shows S-F line: the imaginary line from the medial side of the sigmoid sinus to the fundus of the internal auditory canal.

On the other hand, following drilling of the posterior wall of the IAC, CSF rhinorrhea may result from communication between any extensively pneumatized perimeatal cells and the extracranial mastoid air cells (**Figure 4**). In the meantime, the perimeatal cells may communicate with other pneumatized air cell tract, such as the petrous apex region, peritubal region, and perilabyrinthine region [25]. Neurosurgeons should keep in mind to inspect and adequately obliterate these exposed air cells in the intracranial component while drilling the posterior wall of the IAC. Superior visibility to these anatomical structures of IAC during the surgery would be very helpful to reduce the occurrence of CSF leak postoperatively.

Figure 4: CT bone window depicting well-pneumatized temporal bone in Case15



3 Endoscopic techniques in neurosurgery

3.1 Historical perspective of neuroendoscopy

Endoscopic techniques, developed in response to the increasing demand for less-invasive treatment, are now rapidly expanding their applications in many specialties, such as gynecologic or urologic surgery involving regions of large gas or fluid filled cavities [9, 13, 45]. Since endoscopic techniques allow for

smaller incisions, reduced blood loss, less dissection and minimal retraction, it offers excellent advantages of less postoperative pain, low risk of infection, shorter hospital stay, quick recovery and less scarring [54, 72, 76]. Applying endoscopic techniques to neurosurgery is nothing new but more slowly in neurologic surgical intervention in the past. The stage of neuroendoscopy was inaugurated in 1910 by the urologist L'Espinasse, when he performed the first endoscopic procedure [37]. He placed a rigid endoscope into the dilated ventricular system of a hydrocephalic patient intending to remove the choroid plexus. In the 1920s, Walter Dandy performed a similar procedure on four infants of which one survived [36, 37].

However, in subsequent decades, endoscopes not specifically designed for application within the brain were restricted by primitive technology of lenses and lights at the time. In the meantime, the introduction of microscopy with superior illumination, magnification, and surgical morbidity further dismissed the idea of endoscopy. Surgical techniques and instruments were developed to build the strength and minimize the limitations of operating microscopy. Nevertheless, the drawbacks of microscopy with narrow viewing and working angles in deep operating fields have never been completely solved by neurosurgeons. It was not until the 1970s that the technical drawbacks of earlier endoscopes were solved with the improvement of cameras, lenses and mechanical technologies. Since then intraoperative endoscopes gradually became an effective compensation for the shortcoming of surgical microscopes.

Nowadays, as an integral part of contemporary neurosurgical techniques, neuroendoscopy has been advanced sufficiently to treat a variety of neurosurgical diseases. Modern neuroendoscopy provides a wide angle of view and more depth of focus with high magnification and illumination. In the treatment of hydrocephalus, neuroendoscopic techniques can be used to

reconstitute or recreate the natural pathways of CSF flow, and thereby eliminate the need for the insertion of a shunt system. Endoscopic third ventriculostomy (ETV) has become a new concept for the treatment of occlusive hydrocephalus because of its complications commonly associated with the implantation of shunts to treat hydrocephalus, including shunt malfunction, thrombosis, infection, overdrainage, and slit-ventricle syndrome [23, 39]. Intraventricular lesions are some of the well accepted indicators. Colloid, arachnoid and pineal cysts can be endoscopically fenestrated or removed. Solid intraventricular tumors are preferably biopsied with neuroendoscopic guidance, rather than "blindly" by stereotaxy.

The evolution of neuroendoscopic procedures and growth of indications led to the confused terminology of endoscopic techniques in the treatment of central nerve system disease. Therefore, Hopf et al. systematically classified neurosurgery endoscopic techniques into four groups, as follows: endoscopic neurosurgery (EN), endoscope-assisted microneurosurgery (EAM), endoscope-controlled microneurosurgery (ECM), and endoscopic inspection (EI) (**Table 1**) [40].

Table 1: Hopf classification of endoscopic techniques in neurosurgery

Endoscopic techniques	Manipulations and visualization
Endoscopic neurosurgery (EN)	Endoscopic manipulations under endoscopic control
Endoscope-assisted microneurosurgery (EAM)	Microsurgical manipulations under endoscopic and microscopic control
Endoscope-controlled microneurosurgery (ECM)	Microsurgical manipulations under endoscopic control alone
Endoscopic inspection(EI)	Inspection purposes only

3.2 Endoscopic techniques in the posterior fossa / CPA

Skull base endoscopic techniques presented more challenges than the ventricular system because of its compromising operating space and inability to navigate the lattice of nerves and arteries [52]. The first comprehensive description of endoscopes of the CPA was provided by Doyen, who in 1917 reported an endoscopic technique for selective fifth-nerve section in trigeminal neuralgia [100]. Since the 1990s, a small but ever growing number of surgeons have reported their experiences using the endoscopes to perform microvascular decompression such as the facial nerve for hemifacial spasm, trigeminal nerve for trigeminal neuralgia, glossopharyngeal nerve for glossopharyngeal neuralgia, and cochlear nerve for incapacitating tinnitus [3, 22, 44]. In these studies, endoscopes were used as EI, EAM or ECM during the procedure following retrosigmoid craniotomy. Nerve-vessel contacts usually occur at the root exit zone (REZ) of the nerve. In trigeminal neuralgia patients, compression may even be located within Meckel's cave. Some cases of vascular compression present with multiple vessel contacts was beyond the view of microscopes. All these reasons may lead to failure exposure as a result of inadequate visualization to inspect the lesion under microscopy alone. Endoscopes can bring neurosurgeons' eyes inside the anatomy and help to confirm the nerve-vessel contacts.

Endoscopes allow high magnification and illumination of cranial nerves as well as the basilar artery and its branches with simultaneous reduction in the craniotomy size, thus eliminating or at least reducing the need for retraction of the cerebellum [33, 55]. These factors promote application of endoscopes in other lesions within posterior fossa or CPA. In aneurysm surgery, under endoscopic assistance, the optimal position of the clip can be confirmed, and arteries with potentially detrimental situations following application of the surgical clip can be directly inspected [47, 99]. In vestibular neurectomy

surgery, the greatest advantage of endoscopes is to provide assistance to confirm the vestibular nerve and its relationship to the facial nerve and cochlear nerve. EAM was subsequently performed in the past studies [59, 108].

Poster fossa epidermoids often extend along the plane from the tentorial incisura to the foreman magnum, even from the posterior cranial fossa to the middle cranial fossa. ECM and EAM can be used to completely remove this consistent contents and the capsule adhered to neurovascular via a single small craniotomy [20, 88].

Posterior fossa cysts can be treated effectively and safely via a posterior fossa approach with the help of endoscopic techniques. It's general acceptance that surgical indications are patients with symptoms or mass effect. Nowadays, application of endoscopes in Posterior fossa cysts includes EN for fenestration, EAM or ECM for arachnoid cyst excision, and endoscope-guided proximal catheter placement [27, 29, 87]. Endoscopes provide the ability to explore all aspects of cyst structures and to understand physiology better under minimal craniotomy. Endoscopically burr-hole fenestration and EAM or ECM for arachnoid cyst excision seemed to work better to improve symptoms and decrease a cyst's size than cystoperitoneal shunt, which presented with the high incidence of revision [29].

Since the ideal goal of vestibular schwannoma treatment is radical tumor removal with cranial nerve anatomical and functional preservation without any complication, growing experience with ECM and EAM for management of other CPA pathologies naturally led to application of these techniques for the treatment of vestibular schwannomas. In the 1990s, neurotologists and neurosurgeons had attracted more interest in using endoscopes as an adjunct to microsurgical procedures in vestibular schwannomas [31, 49, 59, 101, 109].

In most literatures, endoscopes were used firstly to identify the relationship between the tumor and neighboring structures, especially the cranial nerves, to avoid improper surgical manipulations. This procedure plays an important role in the function preservation of cranial nerves. Secondly, endoscopes were used to complement the microscope during tumor removal, improve visualization and enabled surgeons to commence delicate procedure. At the end of resection, the last check for completeness of resection was performed. Endoscopes allowed the surgeons to catch hidden vestibular schwannoma behind a cranial nerve, blood vessels, or bone structure on CPA. This is of particular significance while exposing the lateral extent of the tumor. Tatagiba et al. reported the experience that they used rigid angled endoscopes to explore the residual vestibular schwannomas in the fundus of IAC after tumor removal through retrosigmoid approach [101]. Ten years' refinement in endoscopic instrument and surgical skill promoted better postoperative outcomes in this area. Shahinian et al. firstly reported ECM resections of vestibular schwannomas in 2004 and represented 527 patients with excellent results in 2011 [90]. In their last study, total tumor removal was 97.7% (515/527). Anatomic preservation of facial nerve was achieved 100% in all patients. 93% (491/527) of patients retained excellent facial function (H-B grade1/2) and 4% presented with intermediate function (H-B grade3/4). Functional hearing preservation was achieved in 57% (213/374) of patients with preoperative serviceable hearing. No serious postoperative complications occurred.

The development of endoscopic procedures in vestibular schwannomas contributed to the application of endoscopes in IVS surgery. So far, very few literatures have focused on this area [41]. During IVS surgery, as previously mentioned, since it was impossible to open the whole length of IAC through retrosigmoid approach and we have to face the narrow viewing and working angles produced by the remaining posterior wall of IAC with microscopy

application alone, endoscopy seemed to be an effective assistance in the treatment of IVS. The hope of our research is to prove that the retrosigmoid approach integrating EAM with better visualization will be an effective surgical modality in the treatment of IVS.

Patients and Methods

1 Patients

Vestibular schwannomas were classified according to the Hannover classification (**Table 2**) [83, 84]. Patients harboring class T1 or T2 tumors were considered as IVSs in our study. From May 2011 to October 2013, EAM were applied intraoperatively on 24 patients undergoing IVS surgery at the Department of Neurosurgery, Eberhard Karls University Hospital, Tübingen, Germany. All patients were performed via the retrosigmoid suboccipital approach by supine position or semi-sitting position. Collected data included patient age, gender, first symptom duration, pre- and postoperative signs and symptoms, facial motor function, hearing status, complications and completeness of tumor removal. All patients were prepared for surgery by thorough clinical investigation, involving audiometry, CT scan with bone window, and gadolinium-enhanced MRI. The diagnosis of vestibular schwannoma was confirmed histologically in every case.

Table 2 : Hannover vestibular schwannoma classification grade

Grade	Description of Tumor Size
T1	Purely intrameatal
T2	Intra- and extrameatal
T3a	Filling the cerebellopontine cistern
T3b	Reaching the brainstem
T4a	Compressing the brainstem
T4b	Dislocating the brainstem and compressing the fourth ventricle

The adjunctive use of endoscopes during IVS surgery was investigated in all 24 patients. Sixteen of all patients have completed at least 6 months follow-up. In these patients, surgical results, including hearing function, facial nerve function, and completeness of tumor removal, were evaluated at the last follow-up day. Pre- and postoperative facial nerve function was assessed by utilizing the House-Brackmann grading system (**Table 3**) [42]. Audiometry was used to calculate PTA and SDS. It was graded according to the Gardner–Robertson’s (GR) classification (**Table 4**) [28]. Class 1 and 2 were accepted as serviceable hearing (useful hearing). Class 3, 4 and 5 were considered as unserviceable hearing. Postoperative PTA change of less than 10 dB or an SDS less than 15% of the preoperative values was accepted as hearing preservation, otherwise it was considered as hearing could not be preserved. Different tumor sizes (defined as T1 and T2) and preoperative hearing levels (defined as serviceable hearing and unserviceable hearing) were compared respectively by using Fisher’s exact test to determine influencing factors on hearing function preservation in our study. The statistical analysis was performed with SPSS 17.0 (SPSS, Chicago, USA). MRI follow-up examination was used to confirm completeness of tumor removal and recurrence.

Table 3: House-Brackman classification grade

Grade	Description
1	Normal symmetrical function
2	Slight weakness noticeable only on close inspection Complete eye closure with minimal effort Slight asymmetry of smile with maximum effort Synkinesis barely noticeable, contracture, or spasm absent
3	Obvious weakness, but not disfiguring May not be able to lift eyebrow Complete eye closure and strong but asymmetrical mouth movement Obvious, but not disfiguring synkinesis, mass movement or spasm
4	Obvious disfiguring weakness Inability to lift brow Incomplete eye closure and asymmetry of mouth with maximum effort Severe synkinesis, mass movement, spasm
5	Motion barely perceptible Incomplete eye closure, slight movement at corner of mouth Synkinesis, contracture, and spasm usually absent
6	No movement, loss of tone, no synkinesis, contracture, or spasm

Table 4: Gardner–Robertson's hearing classification

Class	PTA (db)	SD (%)
1	0~30	70~100
2	31~50	50~69
3	51~90	5~49
4	90~100	1~4
5	0	0

PTA: Pure-tone averages; SDS: speech discrimination scores;

2 Endoscopic instruments

Bayonet rigid endoscopes (Karl Storz, Tuttlingen, Germany) were introduced measuring 4 mm in diameter with 0- , 30- , and 70- degree lenses. Through a fiber optic cable, the endoscope was linked to a xenon light source and a video camera which fixed with three charge-coupled device sensors connecting to a video monitor to support the high resolution. Images and video were captured and recorded using a digital video recorder system. The endoscope was held by the operating surgeon or connected to a rigid fixation device. Continuous irrigation was performed by the endoscope to ensure the image quality in the operating field.

Figure 5 : Endoscopic instruments (Karl Storz, Tuttlingen, Germany)



3 Surgical procedures

The retrosigmoid suboccipital approach was performed on 24 patients using supine position or semi-sitting position. Somatosensory evoked potential (SEP), BAEP, FMEP, and EMG of the facial nerve were monitored

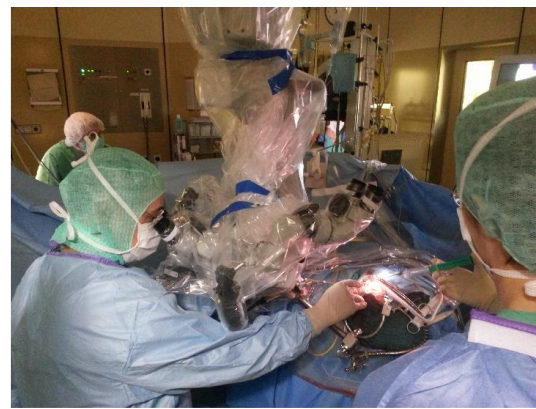
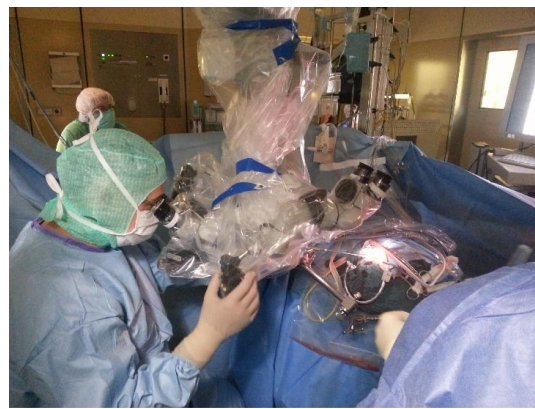continuously by an experienced electrophysiological team.

The dura was opened parallel to sigmoid sinus and transverse sinus. Medial retraction of cerebellum was slightly preformed to expose the partial CPA and the posterior lip of the IAC. After locating the Tübingen line, the dura covering the posterior wall of the IAC was removed. The IAC was carefully drilled out and the dura was opened to expose and remove the intracanalicular tumor that arose from the vestibular nerve. Bone dust was prevented from getting into the subarachnoid space. The lateral end 4~5 mm posterior wall of IAC was left to ensure the intact of the labyrinth. Subsequently, endoscopes were carefully introduced into the IAC and CPA under microscopic control, and related neurovascular structures nearby the tumors were inspected. Endoscope-assisted dissection and resection conducted by microsurgical instruments were performed to keep the neurovascular structure intact in the most lateral part of the canal. The extended part of the T2 tumor outside the IAC was debulked and dissected with microscissors, tumor forceps, and an ultrasonic aspirator.

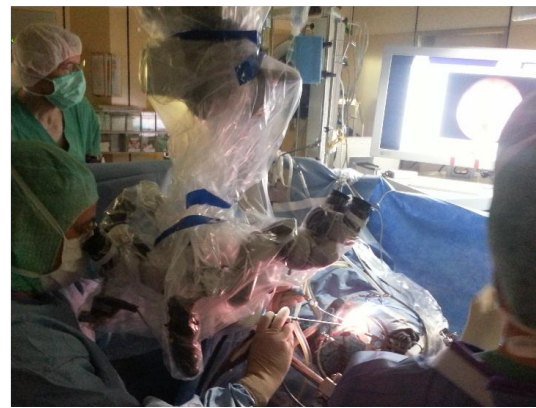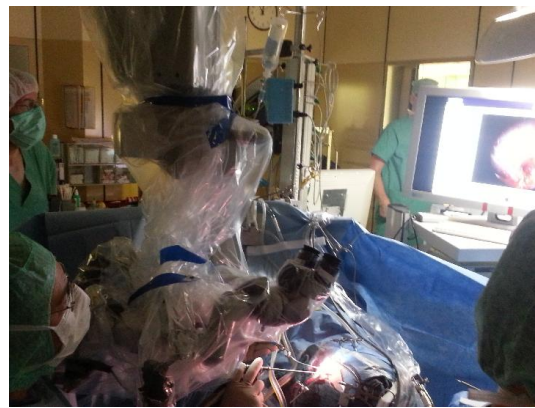After removing the tumor, endoscopes were guided to inspect the IAC and CPA in search of residual tumor at the fundus of the canal or bone air cells opened during the drilling. Under endoscopic direct vision, bone wax was applied to the identified air cells. Fibrin glue and muscle graft harvested from the wound margin were filled in the remaining defect.

At the end of the procedure, the anesthesiologist was responsible for the short jugular vein compression to verify potential blood oozing. The opening dura was closed by a continuous suture in a watertight fashion. The opened mastoid cells were covered with bone wax. Cranioplasty was performed with methylmethacrylate.

Figure 6: Surgical procedures in endoscope-assisted microneurosurgery



The endoscope was carefully introduced into the IAC under microscopic control.



Microsurgical procedures were performed under endoscopic and microscopic control.

Results

The patient population consists of 15 (62.5%) males and 9 (37.5%) females. The age of patients ranged from 11 to 67 years (means 45.1 years). There were 11 (45.8%) T1 tumors and 13 (54.2%) T2 tumors with tumor size according to the Hannover classification. The tumors were located on the right and left side in 13 (54.2%) and 11 (45.8%) of the patients, respectively. The presenting clinical manifestations of the patients are shown in **Table 5**. The most common presentations were hearing deterioration or loss in 15/24 (62.5%); tinnitus in 13 /24 (54.2%); vertigo in 11 / 24 (45.8%); dysequilibrium in 2/24 (8.3%); trigeminal paresthesia in 1 / 24 (4.2%).

The facial function of all the patients preoperatively presented House-Brackmann grade 1. Anatomic preservation of the facial nerve was achieved in 24 (100%) cases accompanied by preservation of intraoperative FMEP monitoring. Postoperative facial weakness was not seen in any of the 16 patients at 6 months follow-up (**Table 6**). A patient with T2 tumor presented slight facial weakness (House-Brackmann grade 2) at the time of discharge and recovered by the 3 month follow-up (Case 7).

Anatomic preservation of the cochlear nerve was achieved in 24 (100%) cases. In 16 patients with at least 6 months follow-up, there were 12 (75%) patients with preoperative serviceable hearing (Gardner–Robertson’s classes 1 and 2). Hearing function was still preserved postoperatively in 9 patients out of all these 12 patients (**Table 6**). Therefore, the serviceable hearing preservation rate was 75% (9/12). Out of 12 cases, only three patients preserved stable amplitude and latency of BAEP monitoring during the surgery (Case 11, 13 and 15). But one case out of these three patients still lost postoperative serviceable hearing (Case 13). There was no difference between tumor sizes (defined as

T1 or T2) with hearing preservation ($p=1.00$, Fisher's exact test). However, patients with preoperative serviceable hearing were significantly more likely to preserve hearing function than those with preoperative unserviceable hearing ($p= 0.001$, Fisher's exact test).

Intraoperative residual tumors in the fundus of IAC which were not caught by the microscopy were identified endoscopically in seven patients out of all 24 patients. In these seven cases, endoscope-assisted resection was performed subsequently. MRI follow-up confirmed the completeness of the tumor resection in 15 cases out of 16 patients with at least 6 months follow-up (**Table 6**). In the other one patient who had neurofibromatosis Type 2 with bilateral vestibular schwannoma, subtotal tumor resection was adopted as a result of the main goal to preserve the nerve function (Case 5).

Endoscopes provided more information to evaluate the tumor and neurovascular relationship than was possible with microscope alone. A 30-degree lens endoscope was more suitable to evaluate in the most lateral part of canal. There were no complications related to the use of endoscopes. No one case of endoscopically thermal or mechanical injury to the cranial nerves, postoperative CSF leak, or other severe complications was encountered. In 9 out of 24 patients, opened air cells were identified by endoscopy alone and bone wax was applied subsequently with its assistance. The use of endoscopes did not significantly increase the operation time as the average endoscopic procedure time was 25 minutes in our study.

Table 5: Clinical features in 24 IVS patients with endoscope-assisted microneurosurgery

Case No.	Sex	Age (Years)	Site	Size	First symptom duration (Months)	Clinical presentation						Postoperative complication
						Hearing loss	vertigo	tinnitus	trigeminal paresthesia	dysequilibrium	Facial weak	CSF leak
1	F	27	Left	T1	24	-*	-	-	-	-	-	-
2	F	42	Right	T1	12	-*	+	+	-	-	-	-
3	M	47	Right	T2	36	+	-	+	-	-	-	-
4	M	58	Left	T1	18	+	-	+	-	-	-	-
5	F	11	Left	T2	60	+*	-	-	-	-	-	-
6	M	44	Left	T2	1	+*	-	-	-	-	-	-
7	M	61	Left	T2	36	+*	-	-	-	-	-	-
8	M	52	Right	T1	24	+*	+	+	-	-	-	-
9	M	41	Right	T1	24	+*	-	+	+	-	-	-
10	M	44	Left	T1	24	+*	-	-	-	-	-	-
11	M	52	Right	T2	24	-*	-	-	-	-	-	-
12	F	43	Left	T2	24	+*	-	+	-	-	-	-
13	F	67	Left	T2	24	-*	+	-	-	+	-	-
14	M	49	Left	T1	24	+	+	+	-	-	-	-
15	F	51	Right	T1	13	-*	+	+	-	+	-	-
16	M	45	Right	T1	216	+	+	-	-	-	-	-
17	M	43	Right	T1	36	-*	+	-	-	-	-	-
18	M	35	Left	T2	9	-*	+	+	-	-	-	-
19	F	36	Right	T2	60	+	-	-	-	-	-	-
20	M	63	Left	T2	540	-*	+	+	-	-	-	-
21	M	30	Left	T1	12	+*	-	-	-	-	-	-
22	F	45	Right	T2	12	+*	-	+	-	-	-	-
23	F	33	Right	T2	12	-*	+	+	-	-	-	-
24	M	46	Left	T2	12	+*	+	+	-	-	-	-

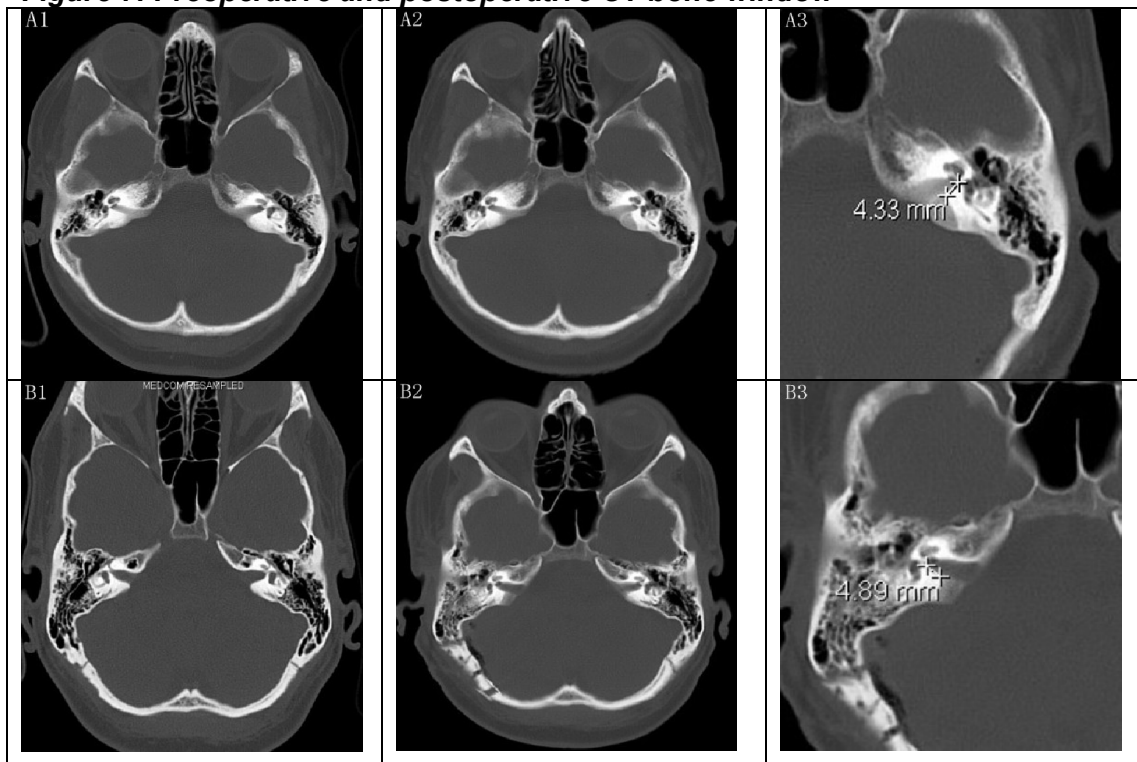
*F: female; M: male; T1: Hannover classification T1; T2: Hannover classification T2; *: serviceable hearing; +: yes or positive; -: no or negative;*

Table 6 : Pre- and postoperative cranial nerves function and completeness of tumor removal in 16 patients with at least 6 months follow-up

Case No.	Size	Preop		Postop		Preop	Postop	Completeness
		PTA (db)	SDS (%)	PTA (db)	SDS (%)	HB Grade	HB Grade	
1	T1	30	90	40	82	1	1	+
2	T1	10	80	15	72	1	1	+
3	T2	70	30	NR	NR	1	1	+
4	T1	NR	NR	NR	NR	1	1	+
5	T2	40	65	40	60	1	1	Subtotal
6	T2	48	54	35	50	1	1	+
7	T2	45	60	NR	NR	1	1#	+
8	T1	50	55	54	60	1	1	+
9	T1	40	60	NR	NR	1	1	+
10	T1	35	68	35	76	1	1	+
11	T2	15	84	25	90	1	1	+
12	T2	40	58	45	50	1	1	+
13	T2	15	88	NR	NR	1	1	+
14	T1	65	25	NR	NR	1	1	+
15	T1	20	90	30	80	1	1	+
16	T1	70	45	NR	NR	1	1	+

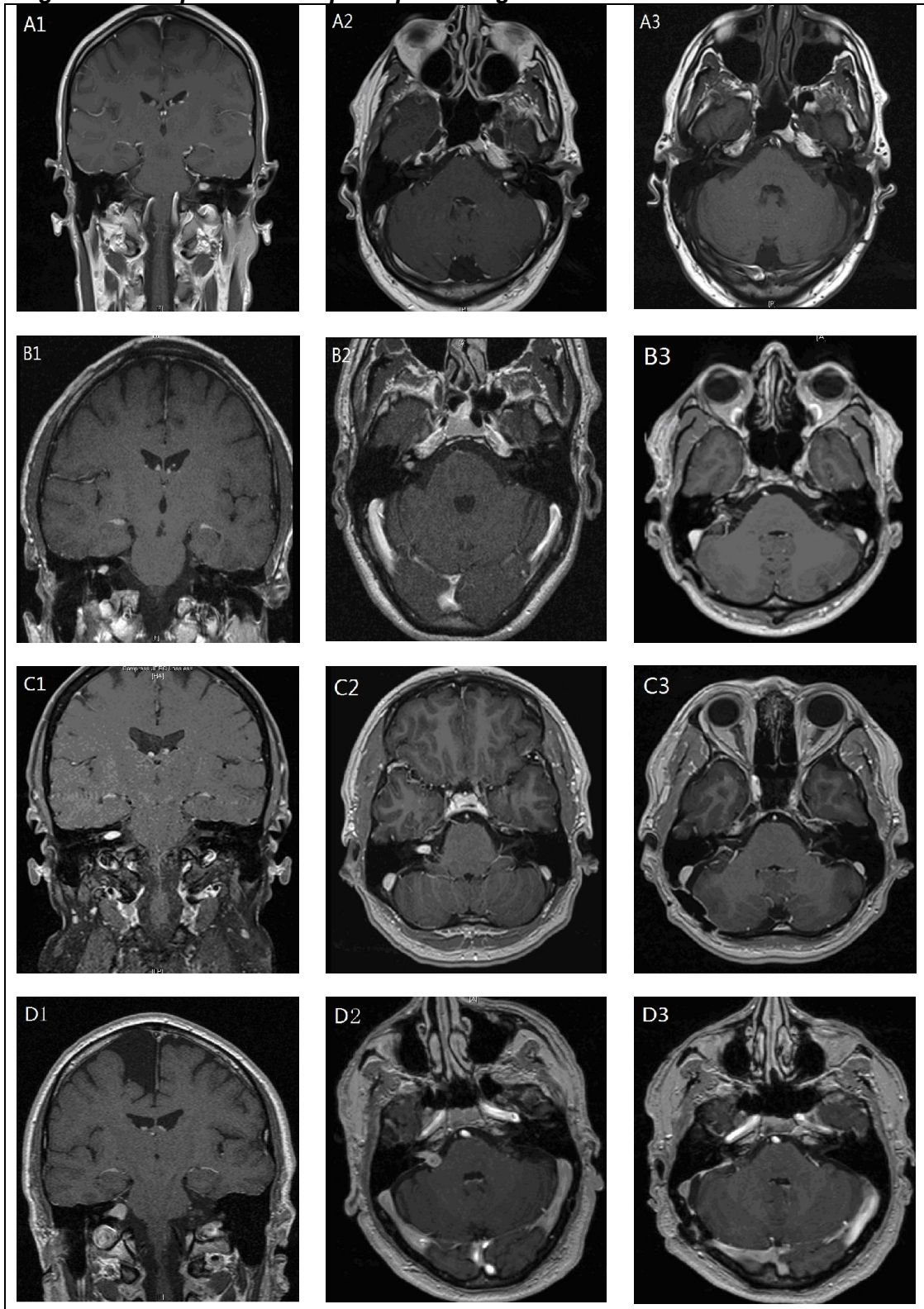
T1: Hannover classification T1; T2: Hannover classification T2; +: yes or positive; -: no or negative; PTA: Pure-tone averages; SDS: speech discrimination scores; NR: no response; HB Grade: House-Brackmann grade; #: House-Brackmann grade 2 at the time of discharge

Figure 7: Preoperative and postoperative CT bone window



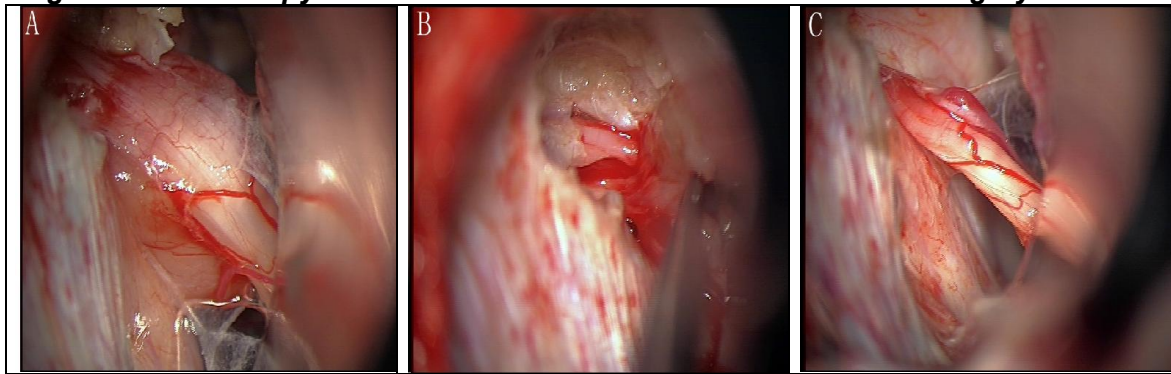
A1: Preoperative CT (case 13); A2, A3: Postoperative CT shows 4.33 mm posterior wall of IAC was remained with the intact of the labyrinth in the left side (case 13); B1: Preoperative CT (case 23); B2, B3: Postoperative CT shows 4.89 mm posterior wall of IAC was remained with the intact of the labyrinth in the right side (case 23);

Figure 8: Preoperative and postoperative gadolinium-enhanced MRI



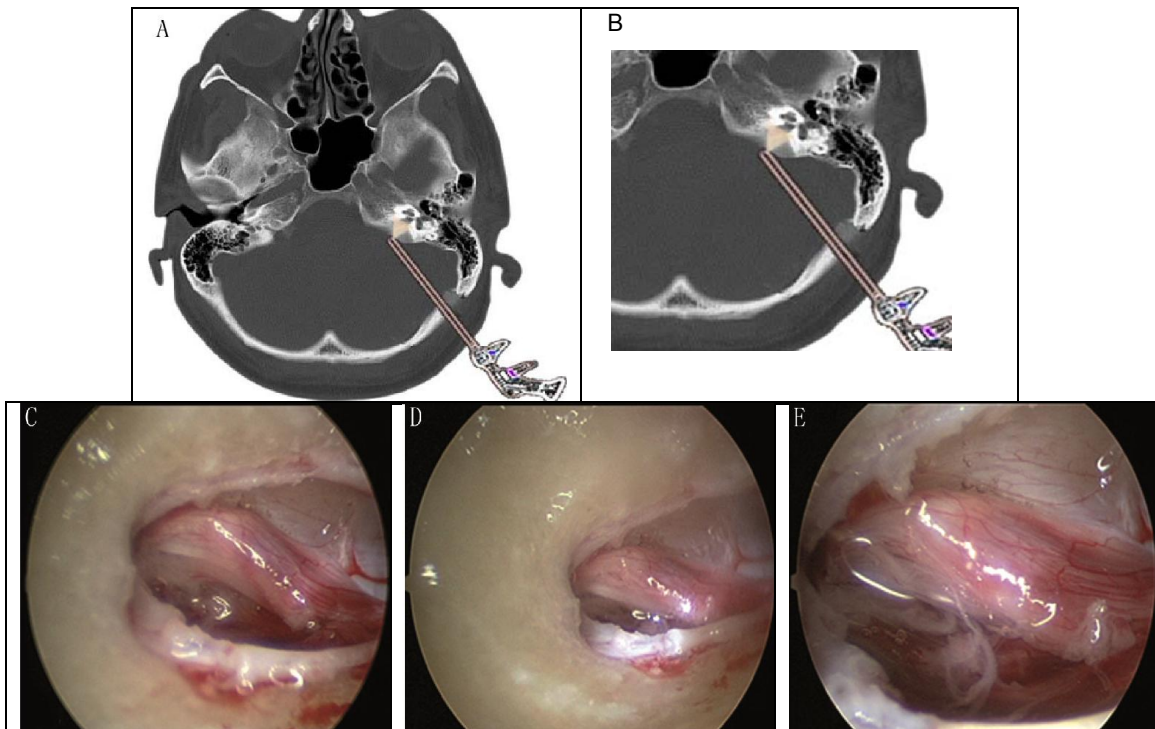
A1, A2: Preoperative MRI (Case 1); A3: Postoperative MRI (Case 1); B1, B2: Preoperative MRI (Case 8); B3: Postoperative MRI (Case 8); C1, C2: Preoperative MRI (Case 10); C3: Postoperative MRI (Case 10); D1, D2: Preoperative MRI (Case 11); D3: Postoperative MRI (Case 11);

Figure 9: Microscopy in intracanalicular vestibular schwannoma surgery



A: CPA was inspected under microscopic control after drilling the posterior wall of IAC. B: The tumor within IAC was evacuated under microscopic control. C: CPA and the medial portion of IAC were inspected under microscopic control after tumor removal.

Figure 10: Endoscopy in intracanalicular vestibular schwannoma surgery



A, B: Schematic diagram of endoscopy in IVS surgery C: The lateral portion of IAC was inspected under endoscopic control after tumor removal. D: Endoscopy was used to inspect potential perimeatal cells. E: The integrity of cranial nerves and completeness of tumor removal were confirmed in the fundus of IAC under endoscopic control.

Discussion

1 Intracanalicular vestibular schwannoma (IVS) surgery

With the advancing operative techniques and intraoperative monitoring, surgical excision of IVS has attracted more interest than ever. In recent years, surgical removal of IVS has become a kind of functional treatment, which aiming to preserve hearing, facial function and related neurovascular integrity, as well as to prevent complications such as CSF leak while completely removing tumors. However, The CPA is rich in neural and vascular structure, especially if the tumor is located within the IAC. The exposure is frequently narrow and difficult. Inadequate illumination is not possible to support the aim of functional treatment with microscope alone. Our study has demonstrated the importance of using endoscopes in the surgery treatment of IVS via the retrosigmoid approach.

Surgical resection of IVS associated with postoperative hearing preservation is performed by the retrosigmoid approach or the middle fossa approach. Although the translabyrinthine approach is also suitable for patients with hearing loss, only the previous two approaches offer the opportunities of improving cochlear function that are important in IVS surgery. In selecting an approach for IVS, the affecting factors include tumor size, tumor sublocalization, preoperative hearing level function and preoperative facial function. However, the results of selecting depend more on the individual surgeon's experience and preference than on the advantages or disadvantages of a particular approach [19, 83]. The retrosigmoid approach provides an extensive operating view of the posterior fossa, and offers the opportunity of cranial nerve preservation, and also is more experienced by neurosurgeons.

The main limitation of the retrosigmoid approach is in gaining exposure of the fundus of IAC due to the restriction imposed by the neighbouring anatomical structure. In our study, the lateral end 4~5 mm posterior wall of IAC remained to ensure the intact of the labyrinth. Supplementary use of angled endoscopes

in IAC helped us to resolve this problem. During the surgery, application of endoscopes enabled operators to inspect and evaluate the tumor and neurovascular structures within IAC and to avoid the blind manipulation at the fundus of IAC which would lead to postoperative sequelae such as tumor residual, cranial nerve dysfunction including hearing loss and facial weakness. At the end of surgery, angled endoscopes provided the ability to visualize bone structures, such as the anterior wall, posterior wall, roof, floor and the fundus within the IAC, which increased the opportunity to obviate the opened air cells and reduce the possibility of CSF rhinorrhea postoperatively.

2 *Practical experiences of endoscopes in IVS surgery*

Compared with the surgical microscopes, endoscopes offered some advantages during our surgical procedures. First, microscopes limited the operation view as it was restricted by the distance of the lens to CPA or IAC, and the viewing angle got narrower along with the focal length, while endoscopes allowed us to move a step further towards achieving these goals. The high magnification in the depth offered excellent definition of the anatomy such as the facial and vestibulocochlear nerves, which greatly facilitated our surgical procedures performed within or around IAC, with the brainstem, between small perforating vessels, or between the cranial nerves. It also helped us to identify the relationship between the tumor and facial and cochlear nerves within the IAC in early stages of surgery. Moreover, after completely removing tumors, endoscopes can also be used to further inspect the fundus for residual tumor and integrity of facial nerve, cochlear nerve and labyrinthine artery, as well as the opened air cells.

Injuring labyrinth after extensive drilling was another drawback of microscopic techniques. Meanwhile, due to its narrow angles in petrous bone and the intervening cerebellum, the fundus of IAC was impossible to reach under direct microscopic view. Endoscopes with angles of 30- and 70-degree lenses enabled us to look around corners or behind obstructions which were beyond the limitation of the microscopically drilled posterior wall. They not only offered

high magnification and illumination in the blind area of the fundus of IAC, but also improved the safety of tumor resection and the visualization of the drilled-out portion of the petrous bone for opened air cells that might need sealing. On the other hand, less bony removal of the posterior wall of the canal became possible with the help of endoscopes with angled lenses. In our study, we usually left the lateral 4~5 mm (rather than 2~3 mm) to ensure the intact of labyrinth. Similar to other studies, we believed a 30-degree endoscope would be more appropriate for visualizing the fundus of IAC [59, 74]. After getting more experience and understanding of endoscopic anatomy in CPA and IAC, we endeavored to limit the size of the exposure and to avoid excessive cerebellum retraction, which might lead to injury as a result of increasing local cerebellar pressure and decreasing regional blood flow. Minimal neurovascular manipulation was possible to reduce postoperative morbidity. We have no one case with postoperative cerebellar hemorrhage or brainstem infarction.

Endoscope-assisted procedures performed in our study did not prolong the operation time. We would not consider the procedure as time-consuming. First of all, we opted EAM over EN. Nowadays, the working channel and surgical instruments of neuroendoscopes available are still too delicate. It is obvious that applying EN procedure even on small solid tumor would extend the operation time. Moreover, microsurgical manipulations, such as using bipolar forceps in hemostasis, seemed more effective and quick during IVS surgery. Secondly, continued irrigation to the endoscopic lens allowed for the clear view and less frequency of wiping lenses. Otherwise it could be a very time-consuming procedure. Thirdly, once endoscopes were introduced, only for a short time, they provided an excellent panoramic view in the depth of CPA and ICA. Only slight shifting of the shaft of the endoscope could achieve various angles of deep-seated anatomical structure during EAM, while traditional microscopic surgery required the surgeons to suspend their procedures, adjust the posture of their neck and body, even the operating chairs, and subsequently refocus the microscopic lens. Each visual angle movement through microscopes seemed more time-consuming compared with endoscopes. In addition, as previously mentioned, supplemental use of

endoscopes promoted small size approach, less cerebellum retraction, minimal arachnoid dissection, and avoidable blind manipulation within IAC, providing the ability to reduce the duration of the whole surgery.

Finally, as a teaching tool, endoscopes offered a superior view of the anatomy for residents and students with the same view and resolution of operators which was often different with traditional microscopic surgery.

Once a strong knowledge of characteristics and maneuvers of endoscopes has been mastered, more precise anatomical relationships that cannot be obtained by microscopes only would be present and then a safe and accurate surgical manipulation would be performed. However, care should still be taken to the following noted points. Firstly, the endoscope provided vision only at its tip. There is a high risk of damaging the normal neurovascular structure while introducing or moving the endoscopes within the CPA or ICA, especially angled endoscopes with a sharp edge [41]. Microsurgical dissection instruments also have the risk of injuring the sensitive and critical structure within ICA even under endoscopic control. Because of lacking overview of the operating field, in our opinion, it is very important to manipulate the shaft of the endoscope and any operating instrument in front of lens under microscopic control to avoid iatrogenic mechanical injury, although keeping eyes on both the microscopic and endoscopic surgical fields at all times is difficult. That is also the reason that we preferred to EAM over ECM in current IVS surgery. In the future, EN with refinement of endoscopic telescopes and instruments through the working channel is likely to ultimately resolve this problem and to develop into a trend of IVS surgery.

Secondly, the xenon light on the tip of the prolonged used endoscope would potentially injure the neurovascular structure. Hori et al. conducted a special thermographic test on using endoscopes in the CPA and suggested that the local temperature associated with the light source did not significantly rise comparing with high-drilling of the posterior wall of the IAC [41]. Although this study did not compare the duration of the use and type of the light source,

based on our experience, the tip of the endoscope may become very hot and still have the opportunity to touch and damage the sensitive neurovascular structures. No one case of our series prompted thermal injury to the postoperative neurological defect. We recommend that regular irrigation is still necessary to protect the healthy tissue. In addition, continuous irrigation by irrigation sheath attached to the endoscope can help to eliminate opacification of the working environment in front of the lens of the endoscope as a result of minor blood soiling.

Thirdly, even though modern lenses of the endoscopes offer a high-resolution image on the video monitor, two dimensional image can still lead to depth misperception. Neurosurgeons may be disorientated under the complicated lattice of nerves and vessels within CPA or IAC. Fraser et al. reported that three dimensional visualization provided by the “Visionsense” endoscopic lens allowed for a high-resolution binocular depth perception in skull base surgery [26]. However, in the absence of three dimensional visions under endoscopic anatomy, neurosurgeons have managed to train their eyes, brain and hands to overcome the limitations. To ensure a safe and secure use of the endoscopic techniques, we believe that establishing a proper system for education and training of endoscopic surgeries is important. There is also a need for clinical experience and training in a certain number of cases. Therefore, mastering endoscopic dexterity and getting three dimensional orientation presents a challenging learning curve to each novice neurosurgeon [49].

Last but not least, since inspection of CPA or ICA requires constant shifting of the field view, the operating surgeon needed to hold the endoscope with one hand. However, the meticulous microsurgical dissection necessitated bimanual surgical technique when a residual tumor was seen in the IAC by endoscopic assistance. Thus, a pneumatic fixation device is necessary to attach the endoscope to ensure safety at allowing bimanual surgical dissection.

3 *Facial nerve function preservation*

In all 24 cases we operated, the facial nerve was anatomically preserved after surgery. Facial nerve function was normal (House-Brackmann grade 1) in 16 (100%) patients at 6 months follow-up. Other studies showed a similar outcome in series in which the retrosigmoid approach was taken [43, 80, 86]. In the studies concerning IVS and postoperative facial nerve function, the middle cranial fossa approach represent 82% to 92% of patients with normal or near-normal function, while the retrosigmoid approach represent 96% to 100% [50]. A meta-analysis of surgical series also reported a statistical significant advantage for the retrosigmoid approach compared to the middle fossa approach [80]. The facial nerve usually lies in anterior and superior in relation to the vestibular schwannoma. In the retrosigmoid approach, the surgeons remove the tumor without violation of facial nerve in the early stage of operation, and facial nerve paralysis does not occur commonly compared to the middle fossa approach. Although the main limitation of the retrosigmoid approach is that it is hard to remove the tumor from the lateral end of the IAC without invading the labyrinth, endoscopes provided excellent visualization in this area to avoid blind dissection behind the facial nerve. Meanwhile, our stable intraoperative FMEP monitoring was able to predict a good postoperative outcome of facial function [1].

4 Hearing preservation in IVS endoscope-assisted surgery

Preserving hearing function presents the most difficult task to achieve in the IVS operations. Keeping the cochlear nerve, cochlear vascular and labyrinthine structures intact is of greatest importance for hearing preservation. In the early stage of operation, use of endoscopes helped to avoid excessive cerebellum retraction. When retracting the cerebellum, tensile force on the cochlear nerve and the cochlear vascular would damage hearing function postoperatively. During the operation, under microscopic and endoscopic control, a delicate bimanual dissection is crucial to preserve the cochlear nerve and labyrinthine artery. Endoscopes permit less bony removal of the posterior wall of the canal to avoid violation of labyrinth. In our study, hearing function

was preserved postoperatively in nine out of all 12 patients who showed preoperative serviceable hearing. Thus, our study reported a better hearing preservation rate (75%) in connection with better visualization assisted by endoscopes. Because there is no consensus about what defined serviceable hearing and preserved hearing, it would be hard to compare the results from different studies. David et al define useful hearing as a PTA ≤ 50 db and SDS $\geq 60\%$ and not strictly to compare some small sample studies on serviceable hearing preservation in IVS surgery [80]. They reported postoperative serviceable hearing preservation ranged 33% to 80% in the retrosigmoid approach. It has been suggested that adjunctive use of endoscopes improve the hearing preservation rate whether in retrosigmoid or middle fossa approach [53, 55]. In our three failure cases to preserve serviceable hearing function, postoperative CT scan with bone window didn't show any fenestrated labyrinth structure. Injury to the labyrinthine artery and ischemia to the cochlear nerve may account for the hearing loss in spite of keeping integrity of the labyrinth and anatomical cochlear nerve [91].

Tumor size and preoperative hearing level are the most significant predicting factors with regard to hearing preservation [73]. Some authors demonstrated that hearing preservation was highly unlikely when the tumor had impacted into the fundus of IAC, which could be found by lacking of a fundus fluid margin on T2-weighted MRI [30, 105]. Most studies did report a significant inverse relationship between tumor size and hearing preservation [18, 58, 60, 73]. A small tumor size means less involvement of the tumor with the nerve as well as less insult at dissection. Better preoperative hearing level indicates the patient's cochlear nerve is in good anatomical and functional condition. Evidence supported by Cohen suggests that a maximum intracanalicular tumor with a diameter of 7 mm can lead to a higher possibility of serviceable postoperative hearing preservation [18]. Furthermore, Moha et al. found that hearing was preserved in 39% of 77 patients with a 15 mm wide tumor or smaller, compared with in 2% of 52 patients with a 16 mm or wider tumor [60]. In a series of cases studied by Mazzoni et al., hearing surgery with success rates for ≤ 10 mm and 20~30db PTA tumors had a good significant relation with

good short- and long-term postoperative hearing preservation hearing [58]. However, Phillips et al. evaluated their data on tumors 10 mm or smaller, and he could not find a critical value that could significantly predict the serviceable hearing preservation [73]. Our study showed no difference between tumor sizes (defined as T1 or T2) with serviceable hearing function. However, only patients with preoperative serviceable hearing function did have the opportunity to improve or preserve their hearing function.

5 *Completeness of IVS removal with endoscopic assistance*

Incomplete tumor excision within the IAC is one drawback of the retrosigmoid approach for vestibular schwannoma surgery. We found that the tumors remnants were identified by endoscopes that were missed by the operative microscopes in 7 patients. By virtue of clear endoscopic visualization of ICA structures in our IVS surgery, total tumor removal was confirmed postoperatively in 15 of our 16 patients with at least 6 months MRI follow-up, which documented no contrast-enhanced lesion with gadolinium DTPA within ICA. However, attempts for radicalization in the fundus can lead to potential sequelae of hearing loss or even facial weakness [17]. In some cases, it was difficult to distinguish tumor from structures of vestibular ganglion or distal stump of vestibular nerves. Neurosurgeons should weigh the balance between the benefit of total removal and the risk of neurological defect. In a patient with neurofibromatosis Type 2, subtotal tumor resection was adopted to preserve the nerve function.

6 *Postoperative complications in endoscope-assisted IVS surgery*

Severe complications including subdural or extradural hemorrhage, brainstem infarction, cerebellar edema or hematoma and dysfunction of lower cranial nerves did not occur in our study. This result was as optimistic as some of the previously published works [17, 32, 34, 49]. It is our belief that endoscopes can help to reduce the morbidity and side effects by minimizing the manipulation, such as the traction of cerebellum.

CSF leak is the most common postoperative complication after vestibular schwannomas removal. It complicates the postoperative course because they can lead to meningitis, reoperation and longer hospital stays. It occurred in 10.6% of retrosigmoid approach cases [89]. CSF rhinorrhea and incisional leaks occurred almost equally with the retrosigmoid approach [7, 89]. Prophylactic techniques, including complete physical obliteration of opened air cells and watertight fashion closure of the opening dural were adapted to prevent CSF leak at the time of the surgery. The endoscopes have proved to be essential in our experience because it provided better view of perimeatal opened air cells that may allow leak into the middle ear and eustachian tube. In nine patients of our study, a 30-degree endoscope was used to identify the exposed air cells after drilling IAC missed by the microscope. Subsequently bone wax was applied to block it with endoscopic assistance. We reinforced the drill-out region of IAC with muscle fascia graft and fibrin glue during closure. In addition, neurosurgeons should keep in mind that increased intracranial pressure may also contribute to the occurrence of leaks. Valtonen et al. compared the rate of CSF leak in 62 vestibular schwannoma cases via the retrosigmoid approach, and they reported CSF rhinorrhea occurred in seven out of 38 (18.4%) operations when no endoscopy was used, whereas no one case occurred in 24 operations in the group using endoscopy [106]. Consistently, there is no one case of CSF leak in our small series.

Conclusion

In recent years, surgical removal of IVS has become one kind of functional treatment. Radical tumor excision with preservation of quality of life is the major goal of IVS surgery treatment. High quality endoscopes with small diameters and various angled lenses allow neurosurgeons to ideally delineate the anatomical structure in deep and narrow space-located lesion of the CPA and IAC during the surgery. Although only limited surgical series were presented in our study, endoscopy did offer several excellent advantages over the conventional microsurgical techniques. Applying endoscopes to the retrosigmoid approach enhances further exposure of the fundus of the IAC while avoiding extensive cerebellar retraction and labyrinthine injury. Endoscopic inspection offers much better visibility to the whole IAC, which is beyond the limit of the microscopes for presence of neoplasm residual and exposed petrous bone air cells. Excellent visualization minimizes the neural manipulation and reduces operation complications with preservation of neurological function. Based on our present experience, we prefer endoscopes as an adjunct tool to IVS microsurgical treatment rather than a fully endoscopic approach. Any movement of endoscopes and microinstrument within the complicated lattice of neurovascular structures may lead to mechanical injury to the health tissue, which could be alleviated by microscopic control. Advancements of endoscopic telescopes and instruments used in the working channel will further empower the endoscope's advantages in the future operations. It is our belief that the improved endoscopic equipment and special training will optimize the outcome of IVS surgical treatment.

References

- [1] M.A. Acioly, M. Liebsch, C.H. Carvalho, A. Gharabaghi, M. Tatagiba, Transcranial electrocortical stimulation to monitor the facial nerve motor function during cerebellopontine angle surgery, *Neurosurgery* 66 (2010) 354-361; discussion 362.
- [2] B.J. Arthurs, R.K. Fairbanks, J.J. Demakas, W.T. Lamoreaux, N.A. Giddings, A.R. Mackay, B.S. Cooke, A.L. Elaimy, C.M. Lee, A review of treatment modalities for vestibular schwannoma, *Neurosurg. Rev.* 34 (2011) 265-277; discussion 277-279.
- [3] M. Badr-El-Dine, H.F. El-Garem, A.M. Talaat, J. Magnan, Endoscopically assisted minimally invasive microvascular decompression of hemifacial spasm, *Otol. Neurotol.* 23 (2002) 122-128.
- [4] M. Barbara, F. Ronchetti, V. Manni, S. Monini, Double localization of a unilateral sporadic vestibular schwannoma, *Acta Otorhinolaryngol. Ital.* 28 (2008) 34-37.
- [5] M.K. Bassim, K.I. Berliner, L.M. Fisher, D.E. Brackmann, R.A. Friedman, Radiation therapy for the treatment of vestibular schwannoma: a critical evaluation of the state of the literature, *Otol. Neurotol.* 31 (2010) 567-573.
- [6] B.L. Bauer, D. Hellwig, Minimally invasive endoscopic neurosurgery--a survey, *Acta Neurochir. Suppl.* 61 (1994) 1-12.
- [7] M. Bennett, D.S. Haynes, Surgical approaches and complications in the removal of vestibular schwannomas. 2007, *Neurosurg. Clin. N. Am.* 19 (2008) 331-343, vii.
- [8] S. Berrettini, F. Ravecca, S. Sellari-Franceschini, P. Bruschini, A. Casani, R. Padolecchia, Acoustic neuroma: correlations between morphology and otoneurological manifestations, *J. Neurol. Sci.* 144 (1996) 24-33.
- [9] F.J. Bianco Jr, B. Guillonneau, Laparoscopic radical prostatectomy: an evolution in surgery, *Minerva Chir.* 60 (2005) 351-362.
- [10] N.H. Blevins, R.K. Jackler, Exposure of the lateral extremity of the internal auditory canal through the retrosigmoid approach: a radioanatomic study, *Otolaryngol. Head Neck Surg.* 111 (1994) 81-90.
- [11] G.A. Bozorg, M. Kalamarides, E. Ferrary, D. Bouccara, G.H. El, A. Rey, O. Sterkers, Conservative management versus surgery for small vestibular schwannomas, *Acta Otolaryngol.* 125 (2005) 1063-1068.
- [12] A. Campero, C. Martins, A. Rhoton Jr, M. Tatagiba, Dural landmark to locate the internal auditory canal in large and giant vestibular schwannomas: the Tübingen line, *Neurosurgery* 69 (2011) 99-102; discussion 102.
- [13] M. Canis, A. Wattiez, G. Mage, J.L. Pouly, J. Raiga, E. Glowaczover, H. Manhes, M.A. Bruhat, Laparoscopic management of adnexal masses, *Baillieres Clin. Obstet. Gynaecol.* 8 (1994) 723-734.
- [14] P. Caye-Thomasen, T. Dethloff, S. Hansen, S.E. Stangerup, J. Thomsen, Hearing in patients with intracanalicular vestibular schwannomas, *Audiol. Neurootol.* 12 (2007) 1-12.
- [15] S. Charabi, M. Tos, J. Thomsen, B. Charabi, M. Mantoni, Vestibular schwannoma growth: the continuing controversy, *Laryngoscope* 110 (2000) 1720-1725.

- [16] S. Charabi, M. Tos, J.C. Thomsen, B.W. Charabi, M.Y. Mantoni, [Vestibular schwannoma. A new interpretation of tumor growth], *Ugeskr. Laeg.* 162 (2000) 5497-5500.
- [17] M. Chovanec, E. Zverina, O. Profant, J. Skrivan, O. Cakrt, J. Lisy, J. Betka, Impact of video-endoscopy on the results of retrosigmoid-transmeatal microsurgery of vestibular schwannoma: prospective study, *Eur. Arch. Otorhinolaryngol.* 270 (2013) 1277-1284.
- [18] N.L. Cohen, W.S. Lewis, J. Ransohoff, Hearing preservation in cerebellopontine angle tumor surgery: the NYU experience 1974-1991, *Am. J. Otol.* 14 (1993) 423-433.
- [19] V. Colletti, F. Fiorino, Is the middle fossa approach the treatment of choice for intracanalicular vestibular schwannoma, *Otolaryngol. Head Neck Surg.* 132 (2005) 459-466.
- [20] de Divitiis O, L.M. Cavallo, Dal Fabbro M, A. Elefante, P. Cappabianca, Freehand dynamic endoscopic resection of an epidermoid tumor of the cerebellopontine angle: technical case report, *Neurosurgery* 61 (2007) E239-240; discussion E240.
- [21] H.G. Deen, M.J. Ebersold, S.G. Harner, C.W. Beatty, M.S. Marion, R.E. Wharen, J.D. Green, L. Quast, Conservative management of acoustic neuroma: an outcome study, *Neurosurgery* 39 (1996) 260-264; discussion 264-266.
- [22] H.F. El-Garem, M. Badr-El-Dine, A.M. Talaat, J. Magnan, Endoscopy as a tool in minimally invasive trigeminal neuralgia surgery, *Otol. Neurotol.* 23 (2002) 132-135.
- [23] Y. Enchev, S. Oi, Historical trends of neuroendoscopic surgical techniques in the treatment of hydrocephalus, *Neurosurg. Rev.* 31 (2008) 249-262.
- [24] N. Fabregas, R.A. Craen, Endoscopic and stereotactic neurosurgery, *Curr Opin Anaesthesiol* 17 (2004) 377-382.
- [25] A.J. Fishman, M.S. Marrinan, J.G. Golfinos, N.L. Cohen, J.T. Roland Jr, Prevention and management of cerebrospinal fluid leak following vestibular schwannoma surgery, *Laryngoscope* 114 (2004) 501-505.
- [26] J.F. Fraser, B. Allen, V.K. Anand, T.H. Schwartz, Three-dimensional neurostereoscopy: subjective and objective comparison to 2D, *Minim. Invasive Neurosurg.* 52 (2009) 25-31.
- [27] M. Gangemi, F. Maiuri, G. Colella, L. Sardo, Endoscopic surgery for large posterior fossa arachnoid cysts, *Minim. Invasive Neurosurg.* 44 (2001) 21-24.
- [28] G. Gardner, J.H. Robertson, Hearing preservation in unilateral acoustic neuroma surgery, *Ann. Otol. Rhinol. Laryngol.* 97 (1988) 55-66.
- [29] N. Gazioglu, A.M. Kafadar, N. Tanriover, B. Abuzayed, H. Biceroglu, N. Ciplak, Endoscopic management of posterior fossa arachnoid cyst in an adult: case report and technical note, *Turk Neurosurg* 20 (2010) 512-518.
- [30] J.C. Goddard, M.S. Schwartz, R.A. Friedman, Fundal fluid as a predictor of hearing preservation in the middle cranial fossa approach for vestibular schwannoma, *Otol. Neurotol.* 31 (2010) 1128-1134.
- [31] N. Goksu, Y. Bayazit, Y. Kemaloglu, Endoscopy of the posterior fossa and dissection of acoustic neuroma, *J. Neurosurg.* 91 (1999) 776-780.
- [32] N. Goksu, Y. Bayazit, Y. Kemaloglu, Endoscopy of the posterior fossa

- and endoscopic dissection of acoustic neuroma, *Neurosurg Focus* 6 (1999) e15.
- [33] N. Goksu, Y.A. Bayazit, I. Bayramoglu, B. Isik, M. Yilmaz, O. Kurtipek, K. Uygur, Surgical exposure in retrosigmoid approach: do we need cerebellar retractors, *Surg. Neurol.* 65 (2006) 631-634; discussion 634.
- [34] N. Goksu, M. Yilmaz, I. Bayramoglu, U. Aydil, Y.A. Bayazit, Evaluation of the results of endoscope-assisted acoustic neuroma surgery through posterior fossa approach, *ORL J. Otorhinolaryngol. Relat. Spec.* 67 (2005) 87-91.
- [35] T.J. Haberkamp, G.A. Meyer, M. Fox, Surgical exposure of the fundus of the internal auditory canal: anatomic limits of the middle fossa versus the retrosigmoid transcanal approach, *Laryngoscope* 108 (1998) 1190-1194.
- [36] L.W. Harris, Endoscopic techniques in neurosurgery, *Microsurgery* 15 (1994) 541-546.
- [37] D. Hellwig, B.L. Bauer, Minimally invasive neurosurgery by means of ultrathin endoscopes, *Acta Neurochir. Suppl. (Wien)*. 54 (1992) 63-68.
- [38] N.J. Hopf, Endoscopic neurosurgery "around the corner" with a rigid endoscope. Technical note, *Minim. Invasive Neurosurg.* 42 (1999) 27-31.
- [39] N.J. Hopf, P. Grunert, G. Fries, K.D. Resch, A. Perneczky, Endoscopic third ventriculostomy: outcome analysis of 100 consecutive procedures, *Neurosurgery* 44 (1999) 795-804; discussion 804-806.
- [40] N.J. Hopf, A. Perneczky, Endoscopic neurosurgery and endoscope-assisted microneurosurgery for the treatment of intracranial cysts, *Neurosurgery* 43 (1998) 1330-1336; discussion 1336-1337.
- [41] T. Hori, Y. Okada, T. Maruyama, M. Chernov, W. Attia, Endoscope-controlled removal of intrameatal vestibular schwannomas, *Minim. Invasive Neurosurg.* 49 (2006) 25-29.
- [42] J.W. House, D.E. Brackmann, Facial nerve grading system, *Otolaryngol. Head Neck Surg.* 93 (1985) 146-147.
- [43] R.M. Irving, R.K. Jackler, L.H. Pitts, Hearing preservation in patients undergoing vestibular schwannoma surgery: comparison of middle fossa and retrosigmoid approaches, *J. Neurosurg.* 88 (1998) 840-845.
- [44] R. Jarrahy, S.T. Cha, J.B. Eby, G. Berci, H.K. Shahinian, Fully endoscopic vascular decompression of the glossopharyngeal nerve, *J. Craniofac. Surg.* 13 (2002) 90-95.
- [45] I. Juhasz-Boss, H. Haggag, S. Baum, S. Kerl, A. Rody, E. Solomayer, Laparoscopic and laparotomic approaches for endometrial cancer treatment: a comprehensive review, *Arch. Gynecol. Obstet.* 286 (2012) 167-172.
- [46] S. Kapoor, S. Batra, K. Carson, J. Shuck, S. Kharkar, R. Gandhi, J. Jackson, J. Wemmer, S. Terezakis, O. Shokek, L. Kleinberg, D. Rigamonti, Long-term outcomes of vestibular schwannomas treated with fractionated stereotactic radiotherapy: an institutional experience, *Int. J. Radiat. Oncol. Biol. Phys.* 81 (2011) 647-653.
- [47] Y. Kato, H. Sano, S. Nagahisa, S. Iwata, K. Yoshida, K. Yamamoto, T. Kanno, Endoscope-assisted microsurgery for cerebral aneurysms, *Minim. Invasive Neurosurg.* 43 (2000) 91-97.
- [48] H.S. Kim, D.I. Kim, I.H. Chung, W.S. Lee, K.Y. Kim, Topographical

- relationship of the facial and vestibulocochlear nerves in the subarachnoid space and internal auditory canal, *AJNR. Am. J. Neuroradiol.* 19 (1998) 1155-1161.
- [49] W.A. King, P.A. Wackym, Endoscope-assisted surgery for acoustic neuromas (vestibular schwannomas): early experience using the rigid Hopkins telescope, *Neurosurgery* 44 (1999) 1095-1100; discussion 1100-1102.
- [50] Y. Kumon, S. Sakaki, K. Kohno, S. Ohta, K. Nakagawa, S. Ohue, S. Murakami, N. Yanagihara, Selection of surgical approaches for small acoustic neurinomas, *Surg. Neurol.* 53 (2000) 52-59; discussion 59-60.
- [51] S.B. Lapsiwala, G.M. Pyle, A.W. Kaemmerle, F.J. Sasse, B. Badie, Correlation between auditory function and internal auditory canal pressure in patients with vestibular schwannomas, *J. Neurosurg.* 96 (2002) 872-876.
- [52] S.C. Lee, B.A. Senior, Endoscopic skull base surgery, *Clin Exp Otorhinolaryngol* 1 (2008) 53-62.
- [53] W.K. Low, Middle cranial fossa approach to the internal auditory Meatus: A Chinese temporal bone study, *ORL J. Otorhinolaryngol. Relat. Spec.* 61 (1999) 142-145.
- [54] J. Ma, M.A. Cassera, G.O. Spaun, C.W. Hammill, P.D. Hansen, S. Aliabadi-Wahle, Randomized controlled trial comparing single-port laparoscopic cholecystectomy and four-port laparoscopic cholecystectomy, *Ann. Surg.* 254 (2011) 22-27.
- [55] J. Magnan, M. Barbieri, R. Mora, S. Murphy, R. Meller, M. Bruzzo, A. Chays, Retrosigmoid approach for small and medium-sized acoustic neuromas, *Otol. Neurotol.* 23 (2002) 141-145.
- [56] N. Massager, O. Nissim, C. Delbrouck, D. Devriendt, P. David, F. Desmedt, D. Wikler, S. Hassid, J. Brotchi, M. Levivier, Role of intracanalicular volumetric and dosimetric parameters on hearing preservation after vestibular schwannoma radiosurgery, *Int. J. Radiat. Oncol. Biol. Phys.* 64 (2006) 1331-1340.
- [57] A. Mazzoni, V. Calabrese, G. Danesi, A modified retrosigmoid approach for direct exposure of the fundus of the internal auditory canal for hearing preservation in acoustic neuroma surgery, *Am. J. Otol.* 21 (2000) 98-109.
- [58] A. Mazzoni, E. Zanoletti, V. Calabrese, Hearing preservation surgery in acoustic neuroma: long-term results, *Acta Otorhinolaryngol. Ital.* 32 (2012) 98-102.
- [59] H. Miyazaki, A. Deveze, J. Magnan, Neuro-otologic surgery through minimally invasive retrosigmoid approach: endoscope assisted microvascular decompression, vestibular neurotomy, and tumor removal, *Laryngoscope* 115 (2005) 1612-1617.
- [60] G. Mohr, B. Sade, J.J. Dufour, J.M. Rappaport, Preservation of hearing in patients undergoing microsurgery for vestibular schwannoma: degree of meatal filling, *J. Neurosurg.* 102 (2005) 1-5.
- [61] E.S. Murphy, G.H. Barnett, M.A. Vogelbaum, G. Neyman, G.H. Stevens, B.H. Cohen, P. Elson, A.D. Vassil, J.H. Suh, Long-term outcomes of Gamma Knife radiosurgery in patients with vestibular schwannomas, *J. Neurosurg.* 114 (2011) 432-440.
- [62] E.S. Murphy, J.H. Suh, Radiotherapy for vestibular schwannomas: a

- critical review, *Int. J. Radiat. Oncol. Biol. Phys.* 79 (2011) 985-997.
- [63] J.J. Nestor, H.W. Korol, S.L. Nutik, R. Smith, The incidence of acoustic neuromas, *Arch. Otolaryngol. Head Neck Surg.* 114 (1988) 680.
- [64] A. Niranjan, L.D. Lunsford, J.C. Flickinger, A. Maitz, D. Kondziolka, Dose reduction improves hearing preservation rates after intracanalicular acoustic tumor radiosurgery, *Neurosurgery* 45 (1999) 753-762; discussion 762-765.
- [65] A. Niranjan, D. Mathieu, J.C. Flickinger, D. Kondziolka, L.D. Lunsford, Hearing preservation after intracanalicular vestibular schwannoma radiosurgery, *Neurosurgery* 63 (2008) 1054-1062; discussion 1062-1063.
- [66] A. Niranjan, D. Mathieu, D. Kondziolka, J.C. Flickinger, L.D. Lunsford, Radiosurgery for intracanalicular vestibular schwannomas, *Prog Neurol Surg* 21 (2008) 192-199.
- [67] R. Noudel, P. Gomis, J. Duntze, D. Marnet, A. Bazin, P.H. Roche, Hearing preservation and facial nerve function after microsurgery for intracanalicular vestibular schwannomas: comparison of middle fossa and retrosigmoid approaches, *Acta Neurochir. (Wien)*. 151 (2009) 935-944; discussion 944-945.
- [68] R. Noudel, T. Ribeiro, P.H. Roche, Microsurgical treatment of intracanalicular vestibular schwannomas, *Prog Neurol Surg* 21 (2008) 183-191.
- [69] O.K. Ogunrinde, D.L. Lunsford, D.S. Kondziolka, D.J. Bissonette, J.C. Flickinger, Cranial nerve preservation after stereotactic radiosurgery of intracanalicular acoustic tumors, *Stereotact. Funct. Neurosurg.* 64 Suppl 1 (1995) 87-97.
- [70] T. Oh, D.T. Nagasawa, B.M. Fong, A. Trang, Q. Gopen, A.T. Parsa, I. Yang, Intraoperative neuromonitoring techniques in the surgical management of acoustic neuromas, *Neurosurg Focus* 33 (2012) E6.
- [71] O. Ozdogmus, O. Sezen, U. Kubilay, E. Saka, U. Duman, T. San, S. Cavdar, Connections between the facial, vestibular and cochlear nerve bundles within the internal auditory canal, *J. Anat.* 205 (2004) 65-75.
- [72] R.O. Parra, M.G. Perez, J.A. Boullier, J.M. Cummings, Comparison between standard flank versus laparoscopic nephrectomy for benign renal disease, *J. Urol.* 153 (1995) 1171-1173; discussion 1173-1174.
- [73] D.J. Phillips, E.J. Kobylarz, De Peralta ET, P.E. Stieg, S.H. Selesnick, Predictive factors of hearing preservation after surgical resection of small vestibular schwannomas, *Otol. Neurotol.* 31 (2010) 1463-1468.
- [74] D.R. Pieper, The endoscopic approach to vestibular schwannomas and posterolateral skull base pathology, *Otolaryngol. Clin. North Am.* 45 (2012) 439-454, x.
- [75] B.E. Pollock, M.J. Link, R.L. Foote, Failure rate of contemporary low-dose radiosurgical technique for vestibular schwannoma, *J. Neurosurg.* 111 (2009) 840-844.
- [76] L.E. Ratner, R.A. Montgomery, L.R. Kavoussi, Laparoscopic live donor nephrectomy: the four year Johns Hopkins University experience, *Nephrol. Dial. Transplant.* 14 (1999) 2090-2093.
- [77] V.V. Raut, R.M. Walsh, A.P. Bath, M.L. Bance, A. Guha, C.H. Tator, J.A. Rutka, Conservative management of vestibular schwannomas - second review of a prospective longitudinal study, *Clin Otolaryngol Allied Sci* 29

- (2004) 505-514.
- [78] J. Regis, R. Carron, M.C. Park, O. Soumare, C. Delsanti, J.M. Thomassin, P.H. Roche, Wait-and-see strategy compared with proactive Gamma Knife surgery in patients with intracanalicular vestibular schwannomas, *J. Neurosurg.* 113 Suppl (2010) 105-111.
- [79] P.H. Roche, O. Soumare, J.M. Thomassin, J. Regis, The wait and see strategy for intracanalicular vestibular schwannomas, *Prog Neurol Surg* 21 (2008) 83-88.
- [80] D.W. Rowed, J.M. Nedzelski, Hearing preservation in the removal of intracanalicular acoustic neuromas via the retrosigmoid approach, *J. Neurosurg.* 86 (1997) 456-461.
- [81] D. Rubinstein, E.J. Sandberg, A.G. Cajade-Law, Anatomy of the facial and vestibulocochlear nerves in the internal auditory canal, *AJNR. Am. J. Neuroradiol.* 17 (1996) 1099-1105.
- [82] M. Samii, V.M. Gerganov, A. Samii, Functional outcome after complete surgical removal of giant vestibular schwannomas, *J. Neurosurg.* 112 (2010) 860-867.
- [83] M. Samii, C. Matthies, Management of 1000 vestibular schwannomas (acoustic neuromas): hearing function in 1000 tumor resections, *Neurosurgery* 40 (1997) 248-260; discussion 260-262.
- [84] M. Samii, C. Matthies, Management of 1000 vestibular schwannomas (acoustic neuromas): surgical management and results with an emphasis on complications and how to avoid them, *Neurosurgery* 40 (1997) 11-21; discussion 21-23.
- [85] M. Samii, C. Matthies, M. Tatagiba, Intracanalicular acoustic neurinomas, *Neurosurgery* 29 (1991) 189-198; discussion 198-199.
- [86] M. Samii, K.E. Turel, G. Penkert, Management of seventh and eighth nerve involvement by cerebellopontine angle tumors, *Clin. Neurosurg.* 32 (1985) 242-272.
- [87] D.I. Sandberg, M.M. Souweidane, Endoscopic-guided proximal catheter placement in treatment of posterior fossa cysts, *Pediatr. Neurosurg.* 30 (1999) 180-185.
- [88] H.W. Schroeder, J. Oertel, M.R. Gaab, Endoscope-assisted microsurgical resection of epidermoid tumors of the cerebellopontine angle, *J. Neurosurg.* 101 (2004) 227-232.
- [89] S.H. Selesnick, J.C. Liu, A. Jen, J. Newman, The incidence of cerebrospinal fluid leak after vestibular schwannoma surgery, *Otol. Neurotol.* 25 (2004) 387-393.
- [90] H.K. Shahinian, Y. Ra, 527 fully endoscopic resections of vestibular schwannomas, *Minim. Invasive Neurosurg.* 54 (2011) 61-67.
- [91] H. Staecker, J.B. Nadol Jr, R. Ojeman, S. Ronner, M.J. McKenna, Hearing preservation in acoustic neuroma surgery: middle fossa versus retrosigmoid approach, *Am. J. Otol.* 21 (2000) 399-404.
- [92] S.E. Stangerup, P. Caye-Thomasen, M. Tos, J. Thomsen, Change in hearing during 'wait and scan' management of patients with vestibular schwannoma, *J. Laryngol. Otol.* 122 (2008) 673-681.
- [93] S.E. Stangerup, J. Thomsen, M. Tos, P. Caye-Thomasen, Long-term hearing preservation in vestibular schwannoma, *Otol. Neurotol.* 31 (2010) 271-275.
- [94] S.E. Stangerup, M. Tos, P. Caye-Thomasen, T. Tos, M. Klokke, J.

- Thomsen, Increasing annual incidence of vestibular schwannoma and age at diagnosis, *J. Laryngol. Otol.* 118 (2004) 622-627.
- [95] J.M. Sterkers, R. Billet, [Small tumors of the acoustic nerve. Their diagnosis and early treatment (apropos of 9 cases)], *Ann. Otolaryngol. Chir. Cervicofac.* 89 (1972) 323-339.
- [96] B. Strasnick, M.E. Glasscock 3rd, D. Haynes, S.O. McMenemy, L.B. Minor, The natural history of untreated acoustic neuromas, *Laryngoscope* 104 (1994) 1115-1119.
- [97] M.E. Sughrue, I. Yang, D. Aranda, K. Lobo, L.H. Pitts, S.W. Cheung, A.T. Parsa, The natural history of untreated sporadic vestibular schwannomas: a comprehensive review of hearing outcomes, *J. Neurosurg.* 112 (2010) 163-167.
- [98] M.E. Sughrue, I. Yang, M.J. Rutkowski, D. Aranda, A.T. Parsa, Preservation of facial nerve function after resection of vestibular schwannoma, *Br. J. Neurosurg.* 24 (2010) 666-671.
- [99] Y. Takaishi, H. Yamashita, N. Tamaki, Cadaveric and clinical study of endoscope-assisted microneurosurgery for cerebral aneurysms using angle-type rigid endoscope, *Kobe J. Med. Sci.* 48 (2002) 1-11.
- [100] Y. Takemura, T. Inoue, T. Morishita, A.L. Rhoton Jr, Comparison of Microscopic and Endoscopic Approaches to the Cerebellopontine Angle.LID - S1878-8750(13)00827-9 [pii]LID - 10.1016/j.wneu.2013.07.013 [doi], *World Neurosurg* (2013) .
- [101] M. Tatagiba, C. Matthies, M. Samii, Microendoscopy of the internal auditory canal in vestibular schwannoma surgery, *Neurosurgery* 38 (1996) 737-740.
- [102] M. Tatagiba, M. Samii, C. Matthies, A.M. el, R. Schonmayr, The significance for postoperative hearing of preserving the labyrinth in acoustic neurinoma surgery, *J. Neurosurg.* 77 (1992) 677-684.
- [103] M. Tos, J. Thomsen, Epidemiology of acoustic neuromas, *J. Laryngol. Otol.* 98 (1984) 685-692.
- [104] M. Tos, J. Thomsen, S. Charabi, Incidence of acoustic neuromas, *Ear. Nose. Throat J.* 71 (1992) 391-393.
- [105] S. Tringali, C. Ferber-Viart, C. Fuchsmann, G. Buiet, S. Zaouche, C. Dubreuil, Hearing preservation in retrosigmoid approach of small vestibular schwannomas: prognostic value of the degree of internal auditory canal filling, *Otol. Neurotol.* 31 (2010) 1469-1472.
- [106] H.J. Valtonen, D.S. Poe, C.B. Heilman, E.C. Tarlov, Endoscopically assisted prevention of cerebrospinal fluid leak in suboccipital acoustic neuroma surgery, *Am. J. Otol.* 18 (1997) 381-385.
- [107] S. Vermeulen, R. Young, A. Posewitz, P. Grimm, J. Blasko, E. Kohler, J. Rasis, Stereotactic radiosurgery toxicity in the treatment of intracanalicular acoustic neuromas: the Seattle Northwest gamma knife experience, *Stereotact. Funct. Neurosurg.* 70 Suppl 1 (1998) 80-87.
- [108] P.A. Wackym, W.A. King, F.G. Barker, D.S. Poe, Endoscope-assisted vestibular neurectomy, *Laryngoscope* 108 (1998) 1787-1793.
- [109] P.A. Wackym, W.A. King, D.S. Poe, G.A. Meyer, R.G. Ojemann, F.G. Barker, P.R. Walsh, H. Staecker, Adjunctive use of endoscopy during acoustic neuroma surgery, *Laryngoscope* 109 (1999) 1193-1201.
- [110] T. Yokoyama, K. Uemura, H. Ryu, K. Hinokuma, S. Nishizawa, S.

Yamamoto, M. Endo, K. Sugiyama, Surgical approach to the internal auditory meatus in acoustic neuroma surgery: significance of preoperative high-resolution computed tomography, *Neurosurgery* 39 (1996) 965-969; discussion 969-970.

Abstract

Objective: The objective of this study was to evaluate the feasibility and efficiency of the endoscope-assisted technique in the surgical treatment of intracanalicular vestibular schwannoma (IVS).

Methods: From May 2011 to October 2013, endoscope-assisted microneurosurgery (EAM) was applied on 24 patients undergoing IVS surgery via the retrosigmoid suboccipital approach. Bayonet rigid endoscopes with 0-, 30- and 70- degree lenses were used to inspect and guide the tumor dissection in the cerebellopontine angle (CPA) and internal auditory canal (IAC) under microscopic control.

Results: No one case of endoscopically thermal or mechanical injury, postoperative cerebrospinal fluid (CSF) leak, or other severe complications was encountered. Endoscopes confirmed the completeness of the tumor resection in 23 cases, as verified in 15 out of 16 patients with at least 6 months MRI follow-up. Anatomic preservation of the facial nerve and cochlear nerve was achieved in 24 (100%) cases. Postoperative facial weakness was never seen in 16 patients with at least 6 months follow-up. Hearing function was preserved postoperatively in 9 (75%) patients out of all 12 patients who showed preoperative serviceable hearing.

Conclusion: Adjunctive use of endoscopy during the retrosigmoid approach can provide more information to evaluate neurovascular relationship, the residual tumor and opened air cells than was possible with microscopy alone, ensuring completed IVS removal and neurological function preservation with less operation complications. It is our belief that the improved endoscopic equipment and special training in the future will optimize the outcome of IVS surgical treatment.

Zusammenfassung

Titel: Der Wert der Endoskopie des inneren Gehörgangs in der Mikrochirurgie des intrakanalikulären Vestibularisschwannome

Ziel: Das Ziel dieser Studie ist, die Machbarkeit und Effizienz der endoskopisch-unterstützten Technik der chirurgische Behandlung des Intracanalikulären Vestibularisschwannom (IVS), zu bewerten.

Methoden: Von Mai 2011 bis Oktober 2013 wurde die endoskopisch-unterstützte Mikroneurochirurgie an 24 Patienten mit IVS, über den retrosigmoidalen subokzipitalen Zugang, angewendet. Das bajonettförmige Endoskop mit 0-, 30- und 70- Grad-Optik wurde zur Inspizierung und Einleitung der Resektion von Tumoren des Kleinhirnbrückenwinkels (CPA) und inneren Gehörgangs (IAC) unter mikroskopischer Kontrolle eingesetzt.

Ergebnisse: Keine thermischen oder mechanischen Verletzungen wurden durch das Endoskop verursacht, ebenso entwickelte keiner der Patienten postoperative Komplikationen oder Liquorrhoeen. Das Endoskop bestätigte die Vollständigkeit der Tumorresektion in 23 von 24 Fällen. Dies bestätigte sich in 15 von 16 MRT-Follow-ups, die mindestens sechs Monate postoperativ gelaufen sind. Anatomische Erhaltung der Nervi Facialis und Cochlearis wurde in allen Fällen erreicht. Postoperative Fazialisparese wurde bei keinen der 16 Patienten mit Follow-up gesehen. Die Erhaltung der Hörfunktion wurde postoperativ bei 9 von 12 Patienten, die präoperativ über Hörvermögen verfügten, festgestellt.

Schlussfolgerungen: Der zusätzliche Einsatz der Endoskopie bei dem retrosigmoidalen Zugang kann mehr Informationen liefern, um über neurovaskuläre Strukturen, sowie Tumorreste und geöffneten Luft-Zellen zu urteilen. Komplette IVS Resektion mit Erhalt der neurologischen Funktionen kann dadurch mit weniger Komplikationen gewährleistet werden. Die

verbesserten endoskopischen Geräte sowie die spezielle Ausbildung hierfür werden in der Zukunft das Ergebnis der IVS Chirurgie optimieren.

Acknowledgment

This work is greatly supported by Prof. Dr. med. Marcos Tatagiba, who patiently provided invaluable guidance and voluminous instruction. His exquisite surgical skills and abundant experience in vestibular schwannoma surgery built the foundation of this research. I have been fortunate enough to have this opportunity to touch this area and enjoy his operation time. In addition, I am very grateful to his unconditional support and constant encouragement during my stay as a clinical and research fellow in Germany.

I would like to thank Prof. Weizhong Yang and Prof. Songsheng Shi at Department of Neurosurgery, Fujian Medical University Union Hospital, who led me into the world of neurosurgery. I express my gratitude for their arrangement of my fellowship project and financial assistance.

Sincere thanks to the staff of Department of Neurosurgery, Eberhard Karls University Hospital, for their assistance throughout the clinical portion of this study. I really appreciate PD Dr. Dr. med. Florian Ebner for his guidance as a mentor in my research, which undoubtedly improve the quality of my thesis. Dr. Ahmed Rizk provided assistance in the construction of the database in my preparatory work. Additionally, I am very grateful to Ms. Susanne Efferenn for her kindly assistance during my fellowship project.

I am really indebted to my beloved family and friends, who helped out during my stay in Germany. Especially to my sister, Xiaodong Song, without her considerable support and encouragement I would not be where I am today. Finally thanks to my wife, Chaoming, for her continued patience, loving support, and great confidence in me through all these years, without which, I would not be in this position.

Curriculum vitae

Name: Shiwei Song
Date of Birth: 21 November 1978
Nationality: China

EXPERIENCE

Clinical and Research Fellow 08/2012– Present
Department of Neurosurgery, Eberhard Karls University Hospital, Germany.
Supervisor: Prof. Dr. med. Marcos Tatagiba

Doctoral Student of Medicine 04/2013– Present
Department of Neurosurgery, Eberhard Karls University Hospital, Germany.
Supervisor: Prof. Dr. med. Marcos Tatagiba

Neurosurgeon 07/2007 – 07/2012
Department of Neurosurgery, Fujian Medical University Union Hospital,
China
Supervisors: Prof. Dr. Weizhong Yang and Prof. Dr. Songsheng Shi

EDUCATION

Master of Medicine 07/2004 – 06/2007
Department of Neurosurgery, Fujian Medical University Union Hospital,
Fuzhou, China
Supervisor: Prof. Dr. Songsheng Shi

Medical Doctor Certification 12/2003

Resident Training 07/2002– 08/2004
Fujian Medical University First Affiliated Hospital, Fuzhou, China

Bachelor of Medicine 07/1997 – 06/2002
Fujian Medical University, Fuzhou, China.